

BINOOCULAR VISION

& StrabOLOGY

Quarterly, Simms-romano's



*

The First and Original Scientific e-Periodical
Devoted to Binocular Vision and Strabismus

*Scientists for the Abrogation of "Statistical Significance = $p \leq .05$ "

*** CORRESPONDENCE ***

FACCIANI and KRAFT: Duane's Syndrome Surgery

VERONNEAU-TROUTMAN: Hugonnier's "Strabology"

POIRIER: Panoramic Exotropia Diplopia

BARRY: Stereo Sue Revisited - Room for Improvement

*** ORIGINAL EVIDENCE-BASED SCIENTIFIC ARTICLES ***

HERTLE: Dynamic Ocular Motor Control and Central Nervous
System Plasticity Promote Novel Discovery and
[Surgical] Therapy of Nystagmus

SHOKIDA, AGUIRRE, and CROXATTO: Trypan Blue Dye for
Strabismus Reoperations, Surgery Complications,
"Slipped" or "Lost" Extraocular Muscles

AHMED, COATS and YEN: Periosteal Flap Fixation of the
Globe for Surgical Treatment of Severe Restrictive
Strabismus: Report of Eight Cases with Outcomes

*** CASE REPORT: Management and Outcome ***

BAGHERI, ERFANIAN-SALIM, SALOUR and YAZDANI: Globe
Fixation with Homologous Temporalis Fascia
Transplant for Treatment of Restrictive Strabismus

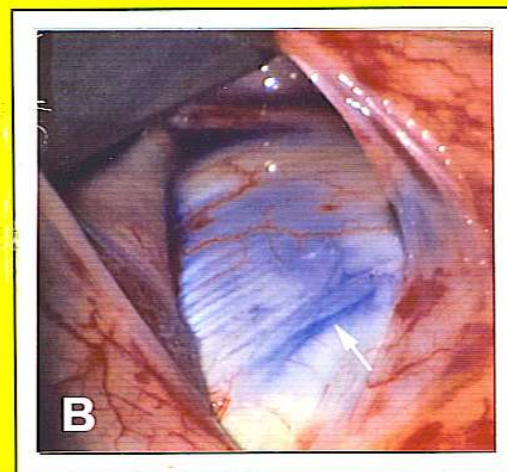
*** EDITORIALS ***

Mission for Orthoptists and Strabologists: What We Are All About

EYE CANDY WORLD: Don't Think, EMOTE! STRABOLOGY
Surgery for Nystagmus; Slip? Trypan Blue; Globe Fixes

Essay: Optically Obvious: Strabometry CLRTs are NOT Binocular

Hyde Park: CONSCIOUSNESS: A Function of Stereoscopic Vision
Via the Egocenter... Machine Vision, Glassless Rims!



FOURTH Quarter, 2011

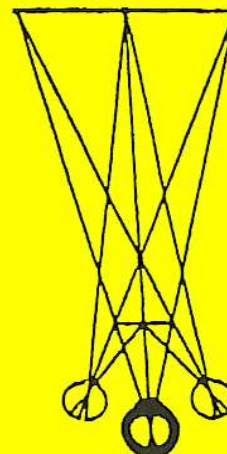
VOLUME 26

NUMBER 4

Winter

Summer

Issue 104, Our 26th Anniversary



binocular

Paul E. Romano, MD, MSO
Founder
Founding Editor
Editor-in-Chief

CITED IN	CITED ONLINE	CITED ONLINE	CITED IN
INDEX MEDICUS	in E M B A S E	in M E D L I N E	INDEX BINOCULUS

An extensive source of products for

Eye Care Professionals



Fun Designer Eye Patches

- Call for Free Patient Samples
- Non-toxic • Latex Free
- Hypo-Allergenic • Breathable
- Aggressive Adhesive
- Blackout layer provides for total occlusion
- Thinner occlusion is gentle on eye lashes


For more than 24 years the Fresnel Prism and Lens Co. has been offering products to assist in the diagnostic and therapeutic issues offered by eyecare specialists.

We are still a small personal office and look forward to working with you to ensure you receive just what you need.




7-Ring Trial Set

- Allow accurate testing of large oculomotor imbalances
- Fits all standard trial frames
- Lightweight - made of thin optical quality acrylic
- Available as two sets providing a full range of prisms
- More accurate evaluation of large-angle deviations
- Indispensable as a tool for the proper evaluation of ocular motility disturbances
- Each set includes a display box

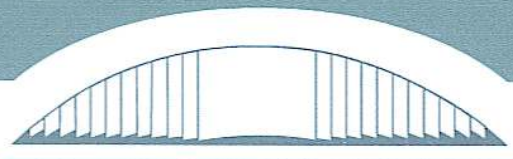


3M Press-On™ Optics

- Ultra-thin prisms and spheres - measure only 1mm thick
- May be cut to fit most frame sizes and shapes and adhere to existing lenses with only water
- Aspheric Lenses - plus and minus and as D-sets
- Diplopia (3rd 4th and 6th nerve palsies, following cataract surgery, myasthenia gravis MS Graves Disease)
- Phorias (symptomatic or decompensated phorias)



Bangerter Occlusion Foils & Bars



**THE FRESNEL PRISM
AND LENS CO.**

1-800-544-4760

www.fresnel-prism.com

info@fresnelprism.com



OUT WITH THE OLD... INTRODUCING OUR NEW ONLINE STORE











RICHMOND PRODUCTS

Examination Products for Ophthalmology, Optometry,
Pediatrics, Neurology, and Occupational Medicine
(505) 275-2406 • Sales@RichmondProducts.com

[Shop](#)[Home](#)[Bookmark](#)[Contact](#)[Sitemap](#)[Log In](#)[Account](#)[Basket](#)[Checkout](#)Search: [All Categories](#)[Go](#)[Advanced Search](#)

FEATURED

 [Adult Near Contrast Test Booklet](#)US \$140.00  [Vertical and Horizontal Prism Set](#)US \$165.00  [Expanded Amsler Booklet](#)US \$60.00  [Brock Strings](#)US \$4.00  [Cardiff Acuity for 6 mos to 3 yrs with Multilingual Instructions](#)US \$1,400.00  [Very Lightly Frosted Occluders](#)US \$14.00 

ACUITY



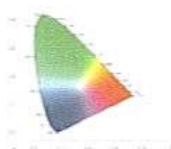
OCCLUDERS AND PATCHES



OPTICS, LENSES AND SETS



BINOCULAR VISION



COLOR VISION



MEDICAL SPECIALTY



DISEASE DETECTION




PATIENT EDUCATION



MULTI-LANGUAGE PRODUCTS



OFFICE TOOLS



JEWELRY AND PROFESSIONAL ATTIRE



OPHTHALMIC NOVELTIES

SHOPPING CART

0 items

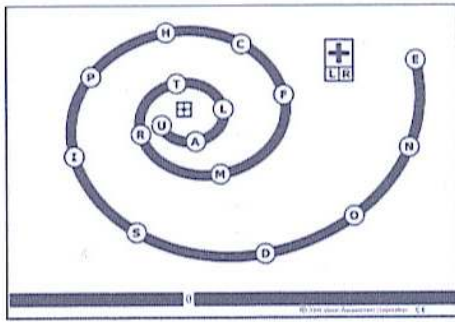
YOU ASKED; WE LISTENED BUYING EYE CARE EXAM TOOLS JUST GOT EASIER.

www.RichmondProducts.com/shop

Use your favorite Smart
Phone QR Code Reader
to access our online store!

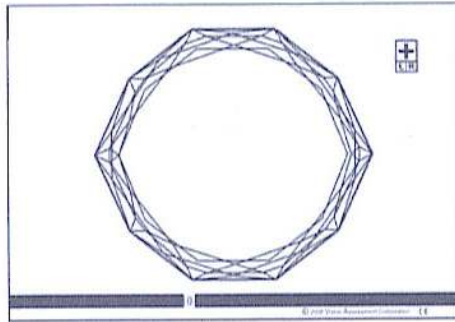


Vectographs for Orthoptic Exercises



Vortex

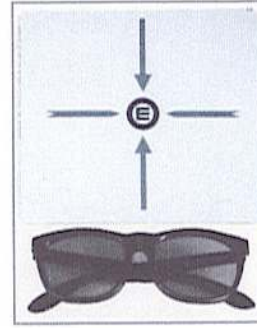
- 40 Diopter Range
- Vortex for esophoria and esotropia
- Gem for exotrophoria and exotropia
- Gem also available with Fusion Lock
- Single and Dual Height Viewers available
- Use Disparity Targets for assessment
- Administer in the office, sell or loan to patients




Gem



Near Fixation



Distance Fixation



Dual Height Viewer

Available at www.RichmondProducts.com
Call 505-275-2406 or E-mail: Sales@RichmondProducts.com



**Treating Amblyopia with
a fun Krafty Eye Patch Kit**
makes eye patching fun
and compliance that much easier



This is how you can display
our patches in your office.

Finally a latex free Adhesive eye patch that doesn't rip
skin or pull out eyebrows when removed!!

For Kids Patching more than once a day
you can reuse this patch!!

Patches are available in Fun Eye Patch kits
or boxed patches.

Please contact us with any questions regarding ordering or samples

858.537.0947

sales@kraftyeyepatches.com

www.kraftyeyepatches.com

BINOCULAR VISION & StrabOLOGY

Quarterly, Simms-romano's

“... the belief that one's view of reality is the only reality is the most dangerous of all delusions ...” -Watzlawick, 1976

EDITOR Paul E. Romano, M.D., M.S.O	ISSN 2160-5351 (Print) ISSN 2160-5904 (Online) TABLE OF CONTENTS	FOURTH Quarter of 2011 Volume 26, Number 4 MEDLINE Abbr. Binocul Vis Strabolog Q Simms Romano NLM ID: 101556982
--	---	--

-
- 199 Correspondence: *John Facciani, M.D.*: Surgical Treatment Technique for Duane's Syndrome
 - 200 Correspondence: *Stephen P. Kraft, M.D.*: Surgical Treatment Technique for Duane's Syndrome
 - 201 Correspondence: *Suzanne Veronneau-Troutman, M.D.*: Hugonnier's "Strabology"
 - 202 Correspondence: *Vicki Poirier, B.Ed.*: Panoramic Exotropia Diplopia
 - 203 Correspondence: *Susan R. Barry, Ph.D.*: Strabology - Room for Improvement
 - 205 Editorial: Renewal of (Moral) Mission Objectives for Orthoptists and Strabologists:
What We Are All About
 - 207 Editorial: EYE CANDY WORLD: Don't Think, EMOTE! STRABOLOGY Surgery for Nystagmus;
Slip? Trypan Blue; Globe Fixes.
-

*** ORIGINAL "EVIDENCE-BASED" SCIENTIFIC ARTICLES ***

- 210 Binocular Ocular Motility: Breaking with the Past: How Understanding Dynamic Ocular Motor Control and Central Nervous System Plasticity Promote Novel Discovery and [Surgical] Therapy of Nystagmus. *Richard W. Hertle, M.D.*
- 222 The Use of Trypan Blue Dye for Strabismus Reoperations, Surgery Complications, and Especially for the Identification and Recovery of a "Slipped" or "Lost" Extraocular Muscle. *Felisa Shokida, M.D., Rodolfo Aguirre, M.D. and Oscar Croxatto, M.D.*
- 230 Periosteal Flap Fixation of the Globe for Surgical Treatment of Severe Restrictive Strabismus. A Report of Eight Cases with Outcomes.
Rehan Ahmed, M.D., David K. Coats, M.D. and Michael T. Yen, M.D.

*** CASE REPORT with Management, Outcome and Literature Review ***

- 236 Globe Fixation with Homologous Temporalis Fascia Transplant for Treatment of Restrictive Esotropia Strabismus: An Interventional Case Report and Review of the Literature.
Abbas Bagheri, M.D., Reza Erfanian-Salim, M.D. Hossein Salour, M.D., and Shahin Yazdani, M.D.

-
- 243 Editorial Essay: Optically Obvious: Strabometry: CLRTs are Tester (EXAMINER) MONOCULAR tests, NOT Binocular
 - 246 Abstracts of the Current Literature
 - 248 Hyde Park Editorial: CONSCIOUSNESS: A Function of Stereoscopic Vision via the Egocenter. Machine Vision, Glassless Rims ...
-

Index of Advertisers:	Fresnel Prism and Lens Co. Richmond Products Savko Optical. Krafty Eye Patches International Orthoptic Association	Page 194 Page 195, 196 Page 196 Page 245
------------------------------	---	---

Leonard Apt
Robert W. Arnold
Kyle Arnoldi
E.S. Avetisov, Russia
John D. Baker
P. Vital Berard, France
Frank Billson, Australia
Michael C. Brodsky
Jorge A. Caldeira, Brazil
Alberto O. Ciancia, Argentina
Kenneth J. Ciuffreda
David K. Coats
Jeffrey Cooper
Jan-T.H.N. de Faber, Netherlands
Jay M. Enoch
Robert W. Enzenauer
Caleb Gonzalez
Michael H. Graf, Germany
David Guyton
Eugene M. Helveston
Richard W. Hertle
Creig S. Hoyt
Robert S. Jampel
Edward Khawam, Lebanon

Lionel Kowal, Australia
Stephen P. Kraft, Canada
Joseph Lang, Switzerland
Malcolm L. Mazow
Henry S. Metz
Joel Miller
James L. Mims III
Scott E. Olitsky
Gian Paolo Paliaga, Italy
Evelyn A. Paysse
J.V. Plenty, United Kingdom
Zane F. Pollard
Julio Prieto-Diaz, Argentina
Edward L. Raab
Michael X. Repka
James D. Reynolds
David L. Romero-Apis, Mexico
Alan B. Scott
Kurt Simons
Annette Spielmann, France
David R. Stager, Sr.
Martin J. Steinbach, Canada
David S.I. Taylor, England
Guillermo Velez, Colombia

Bruce C. Wick
M. Edward Wilson, Jr
Kenneth W. Wright
EMERITUS
Shinobu Awaya, Japan
Henderson Almeida, Brazil
Bruno Bagolini, Italy
Albert W. Biglan
Eileen Birch
William N. Clarke, Canada
John S. Crawford†, Canada
Robert A. Crone, Netherlands
Eugene R. Folk†
David A. Hiles
David Hubel
Bela Julesz
Herbert Kaufmann, Germany
Philip Knappt
Burton J. Kushner
John P. Lee†, England
Pinhas Nemet, Israel
Robert D. Reinecke
William E. Scott
R. Lawrence Tychsen

BINOCULAR VISION & STRABOLOGY QUARTERLY, Simms-Romano's: Print Version **ISSN 2160-5351** formerly most recently 1088-6281 (LIMITED PRINT version for libraries), since 2007 addition of identical electronic Internet ONLINE version, **ISSN 2160-5904**,

The "loftiest scientific journal in the world" is published 9100 feet above sea level, in the Rocky Mountains, in the shadow of the American Continental Divide, Summit County, Colorado, by **BINOCULUS PUBLISHING**, PO Box 3727, 740 Piney Acres Circle, Dillon, CO 80435-3727 USA; FAX 970-262-2768. Email: judyatbv@vail.net. A Medical Scientific online E-Periodical(with continuation of limited print version for libraries.

Webmaster: Ryan Soderberg, Webez.net Internet Services, Dillon, Colorado. Official publication date of this issue October 1, 2011 Distribution date by December 31, 2011. This is a Simms-Romano Enterprise (Simms is the maiden name of the founder's mother, R.N., a Daughter of the American Revolution, (DAR), honored here as the laudable custom in many other world cultures; his father was Battalion Surgeon for the 33rd Infantry Division in World War II, serving from 1942-1945, in the Pacific; scheduled to invade Japan, when Hiroshima saved his life and those of many other Americans and Japanese.).

COPYRIGHT 2011. All rights reserved. No part of this publication may be reproduced or transmitted in any form or by any means, electronic or mechanical, including xerographic copy, photocopy, recording, or an information storage and retrieval system, without permission in writing from the publisher, except as specifically allowed by law (each paid subscriber may print one hard copy of each issue, for personal use only, by simply executing the "print" command on their computer/printer).

EDITORIAL OFFICE / MANUSCRIPTS: Please send by email to the Editor, **Binocular Vision & Strabology Quarterly**, at perxbvq@colorado.net, with a copy to judyatbv@vail.net. Instructions for Authors may be found on the website (binocularvision.net) or by contacting judyatbv@vail.net and a PDF will be sent to you. **Letters to the Editor** are considered "for publication" unless otherwise indicated and may be edited and condensed as space dictates.

ADVERTISING: Please direct inquiries to BINOCULUS PUBLISHING, PO Box 3727, 740 Piney Acres Circle, Dillon CO 80435-3727 USA. Tel & FAX 970-262-0753. Media kit and rates on request.

SUBSCRIPTIONS: For 2011 Please send orders with check or money order payable in US \$ funds to Binocular Publishing, PO Box 3727, 740 Piney Acres Circle, Dillon CO 80435-3727 USA. **Visa, Mastercard and American Express** are accepted. To subscribe or order, Call/Fax 970-262-0753. Email: Judy Robinson <judyatbv@vail.net> Or order on the (secured) website at www.binocularvision.net (Personal, one year subscriptions

Individual: Per four issue online electronic annual volume only: \$68 a year for a three year subscription (total \$US 204 =3x68), \$78 a year for a two year subscription (\$US 156 =2x78), \$84 for a one year subscription. Special reduced rates available for Certified Orthoptists, see International Orthoptic Association.com Rendered by quarterly email hot link.

Library/Institution: one year **online electronic** subscription \$US 426, online electronic version only. For an additional second subscription in print, \$US395

Open online access store: BinocularVision.net. Single Issues \$US 47, individual articles \$US 7-37

Back print issues (1985-2010) \$US 36, if available only) Some past Bound Volumes are available thru'2005.

Disclaimer: The ideas/opinions expressed in **Binocular Vision & Strabology Quarterly** do not necessarily reflect those of the publisher or editorial staff. **BV&Sq** makes every effort to maintain accuracy; however, cannot guarantee accuracy of contents. or claims of advertisers. Readers should consult the author or manufacturer before using any product appearing in **BV&Sq**.

The designation of individual issues is by the quarter, not the season, because seasons are never the same, but opposite, in the Northern and Southern hemispheres. The seasons are however designated on the cover with the Northern season on the top and, inverted below, the current season in the Southern hemisphere.

Letters [copied] to the Editor to facilitate connections, email
about a recently published article in this publication:

Re: Kraft SP: **Resecting the Lateral Rectus in Unilateral Duane Syndrome**
with Esotropia and Limited Abduction. *Binocular Vis Strab Q* 2010:149-157

-----Original Message-----

From: John Facciani [mailto:johnfacciani@gmail.com]
Sent: Monday, July 04, 2011 0:43
To: Stephen Kraft
Subject: Duanes resections

johnfacciani@gmail.com

Steve- thanks for the July 4th wishes. I was interested if you could tell me which Esotropic patients do best with small lateral resections? Do you do these with patients with -4 abduction. What sort of deviation do they have pre-op in primary? What amount of face turn is correctable?

How do

You decide how much medial recession or lateral resection to do? I am very interested in hearing more about your experience with this technique. Thank you in advance!

Sent from my iPhone

This e-mail may contain confidential, personal and/or health information (information which may be subject to legal restrictions on use, retention and/or disclosure) for the sole use of the intended recipient. Any review or distribution by anyone other than the person for whom it was originally intended is strictly prohibited. If you have received this e-mail in error, please contact the sender and delete all copies.

In Reply:

From: "Stephen Kraft" <stephen.kraft@sickkids.ca>
To: "John Facciani" <johnfacciani@gmail.com>
Cc: "Paul E. Romano" <perxbvq@colorado.net>; "Judy Robinson,CO,COT" <judyatbv@vail.net>
Sent: Monday, July 04, 2011 12:11 PM
Subject: RE: Duanes resections
John

Here are my criteria for using a MR recess and (small) LR res for Duane (Note that all have to present !):

1. Esotropia at least 25 PD in primary position
2. Yes -- abduction -4
3. Combination of 3 clinical features that suggest LR co-contraction phenomenon is minimal:
 - a) No limitation of adduction clinically (even though it is truly there in almost all Duane cases -- hidden in these occasional cases by the fact the eye is retracted into the orbit)
 - b) Minimal change in eyelid fissure height on adduction (less than one-third decrease comparing primary position to adduction)
 - c) Mild or no upshoot/downshoot on adduction
4. Some tightness of MR on forced duction at surgery.

So if you think about your own cases, there are not a lot of these "perfect" cases that would provide opportunities to use the R and R. I have only had a handful in the past few years.

If you want the full dissertation and data, I have published my experience in Paul Romano's journal, Binocular Vision, within the last year:

Kraft SP: Resecting the lateral rectus in unilateral Duane syndrome with esotropia and limited abduction. Binoc Vis Strab Q 2010; 25: 149 - 157.

I would normally send you the pdf, but due to copyright issues you would have to contact Paul or Judy to get permission for them to send you a copy of the paper (perxbvq@colorado.net; judyatbv@vail.net)

Let me know if you do a case -- so far I have had good results that justified the resection.

Cheers
Steve

BV&SQ did send Dr. Facciani a copy of Dr.Kraft's paper. -per

Judy Robinson,CO,COT

From: "Richard Troutman MD" <veronneautroutman@msn.com>
To: "Judy Robinson,CO,COT" <judyatbv@vail.net>; <perxpvq@colorado.net>
Sent: Tuesday, December 14, 2010 12:37 PM
Subject: Re: R. HUGONNIER'S 'STRABOLOGY'

Dear Ms. Robinson,,

The term "Strabologue" (between quotes) is used by Hugonnier in the 1959 first edition of *Strabismes, Heterophories et Paralysies Oculo-motrices*. In the .1969 English Edition that I translated and edited *Strabismus, heterophoria and ocular motor paralysis*, see ref. 1, I used the term Strabismology, because of term Strabismus in English. In French the Term Strabologie corresponds to Strabisme.

See Definition Glossary page 16 see ref 1, *Strabismology*: A term used for a number of years to designate the study of all that relates to binocular vision and the pathology of extraocular muscles. This word is perhaps etymologically disputable, however, it is now accepted and should be retained.

In the 1970 French Edition you can read the corresponding French definition.

NB:For my part I have always used in English the terms *Strabismology* and *Strabismologist*.

Unfortunately Both Hugonniers have been deceased for many years.

Say Hello to Dr. Romano for us . Fortunately both of us are still alive!

Suzanne Veronneau-Trioutman MD

Ref 1: Veronneau-Troutman S, Translated and Edited: Hugonnier R, Hugonnier SC, *Strabismus, Heterophoria, and Ocular Motor Paralysis*, First English Edition, St Louis CV Mosby 1969, 709 pp.

Letter to the Editor: **[Strabology: Room for Improvement:]** A less than desirable Outcome to Treatment of Strabismus and Loss of Binocular Vision: A personal account from a fellow auto enthusiast who was also a strabismus patient elsewhere, and in adulthood makes the most of her yet binocular misalignment and **[PANORAMIC XT DIPLOPIA :]**

Unique Optical Situation

During my delivery in 1958 the doctor poked me in the right eye with forceps causing my right eye to have a hole in it, and damaging the muscle tissue badly. The damage was on the side closest to the nose resulting in the eye looking sharply toward the nose. For my first 13 months of life my wrists were tied to a crib so I would not try to scratch my eyes.

My Optometrist, Doctor Book moved muscle tissue from one side of the eye to the other trying to even out the muscles so the eye would look straight. I had way more than a dozen surgeries, perhaps 26 all together over 14 years. Dr. Book did everything he could to try and make me look straight. Eyes are supposed to be looking toward a centre point, but mine look straight out. They look ok when someone looks at me, but it does result in needing prisms in my glasses so that I don't have a slight double vision.

I'm sure Dr. Book would have liked to give me at least one more operation to tweak them just a little but I had had enough. My very last operation at 14 years old did not go as planned. The freezing wore off and I woke up in the middle of him digging around in my eye. The pain was excruciating but I was paralyzed. I couldn't move or speak, and my eyes were in these tools that hold the eyes wide open. I started tearing up like crazy and that was when he realized I was awake and so he knocked me out again. When I did finally wake up, I said, "this will never happen again". This resulted in me living with eyes that work independently: they look straight out, or diverge a little, rather than towards a common point.

This came in quite handy as a teen and still does today. For instance, when I was in Junior High School I could copy notes from a friend in record time for classes I had missed, by simply putting one eye on what I was copying and one eye on what I was writing. In addition, when marking tests as a young teacher or when marking papers at a TSD Rally, I can look at the answer sheet and compare it to the test at the same time very quickly because there is no need to look back and forth like most people. I simply put one eye on each paper, and scan and compare.

Here's another example of how my eyes are quite handy just the way they are. Imagine you are reading a document on the computer and you now have to move your mouse up to the right and drag the long box down so you can see the rest of the document. I can do that with one eye while continuing to read the whole time. I don't even have to think about it. The one eye just goes off and does a small task while the other eye and the brain are concentrating on what it is reading.

I can also put lipstick on in the rearview mirror with one eye while my attention is still focused on the road ahead. This is just another simple task on the side made better with my unique advantage.

Vicki Lynn Poirier, B.Ed
Winnipeg, Manitoba CANADA
MSSS Judge and Road Race Official

Letters to (previously) for the Editor to reprint now, the right moment (See Editorial, page 205-206). This, like the prior Letter to the Editor, previous page, can be similarly introduced:

Strabology: Room for Improvement: A less than desirable Outcome to Treatment of Strabismus and Associated Deficiencies of Binocular Vision by Strabology Surgeons and Ophthalmologists: A personal account from a neuroscientist who was also a strabismus patient elsewhere, in infancy, and with optometric help and “vision training” in adulthood, normalizes her imperfect residual binocular misalignment and latent nystagmus to regain normal binocular single vision and fully normal stereoscopic depth perception, which gives her great joy and enjoyment. ? Why can't, why didn't an Orthoptist do this?

This New England neuroscientist is Susan R. Barry, PhD, whose dramatic story was engineered and reported by neurologist Oliver Sacks, MD, in the *New Yorker* Magazine, (June 19, 2006); then immediately reprinted in this publication five years ago (2006; 21(3):160-169); and then we published her letter, which she wrote in reply to a note to the *New Yorker* from our Ed Board member James L. Mims III, in the following issue (2006; 21(4):199-202). Dr. Barry has also written a book about her experience: “Fixing my Gaze. A Scientist's Journey into Seeing in Three Dimensions”. (Basic Books, New York, 2009. ISBN:978-0-465-00913-8), a very detailed and enlightening account.

Dr. Mims had written to author Dr. Sacks at the *New Yorker*, with copy to us, with a giant “BUT” about her recovery, listing in superb detail and in review and reference all the various and possible ways that Dr. Barry's gaining of fully normal 3D stereoscopic depth perception in adulthood maybe **wasn't so amazing**.

Dr. Barry replied with complete and full details of her strabismus condition and its management which refuted and/or virtually eliminated all of Dr.Mims' alternate scenarios and explanations he had used to excuse ophthalmologists for her predicament and that of the large majority of our strabismus patients who not did obtain full cures of strabismus with restoration of normal binocular vision and stereopsis as she had pointed out so accurately..

BUT, we thought that he also overlooked the most important point of her experience, and report, most critical FOR US AS Eye MDs, that she had vision problems and no stereopsis at that point in time IN ADULTHOOD, and the MD eye doctors in our medical specialty had “thrown in the towel” on any such possibility of recovery and normalization, given up... BUT that someone in optometry with no different tools than we all have, but with motivation and a different sense of duty ?, a higher medical goal (“a cure”) than eye MDs apparently have ?, DID accomplish this for her.

To this purpose we wish only to here quote again a few lines of the items she has already

written in her letter which we have published (see second reference above): Stereo Sue says:

“... After ‘Stereo Sue’ was published and my story was aired on NPR’s Morning Edition (see <http://news.wnpr.org/templates/story/story.php?storyId=5507789>), I received more than 100 emails specifically from strabismics and amblyopes. Many had had [strabismus] surgery, and all had been told that nothing more could be done for their vision, that it would not be possible for them to obtain binocular vision ...

“ In my perusal of the clinical literature on strabismus, I have discovered that results from strabismic surgery are quite variable. **Less than half of the children who receive surgery in the first year of life develop measurable stereoacuity, and very few develop fine stereopsis** (Birch et al., 2004. Am J Oph. 138:1002-9). Moreover, von Noorden included **reduced or even absent stereopsis as a valid criterion for a successful surgical outcome** (Von Noorden, 1988. Am J Oph. 105-1-10). Thus, even children who receive the **best of ophthalmic care** in infancy may still go through life with compromised vision. You state in your letter that your goal is to restore stereopsis in strabismic infants. Optometric vision therapy provides an additional and powerful tool in a doctor’s arsenal to improve a child’s binocular vision. As a patient who required both surgery AND optometric vision therapy to achieve stereopsis,. **I encourage you to examine optometric vision therapy with a critical but objective eye, and I would be more than willing to help out in any manner”**

[bolding for Ed emphasis -per]

Sincerely yours,

signature

Susan R. Barry. PhD.

Associate Professor of Biological Sciences

Mount Holyoke College

South Hadley, Massachusetts 01075

sbarry@mtholyoke.edu

We intend to publish a detailed review of her book in the near future, which book sets out the many non surgical exercises and procedures they used and anyone else can too..

So go back and take a look at the originals we published, or get a copy of her book “**Fixing My Gaze**” and read it. **BV&SQ will give you \$ 13 if you send us your receipt.**

Basic Books

Price: US\$26

387 Park Avenue South,

New York, NY 10016.

ISBN: 978-0-465-00913-8

And please read my following editorial plea. -per

EDITORIAL: Renewal of (Moral) Mission Objectives: for Orthoptists and Strabologists: What we are all about:

Vision> x2 >>Stereopsis >3D World >>Egocentric Localization Therein

If you have read any of our Hyde Park Editorials in the recent past, you know this editor has declared that stereoscopic vision, which enables our three dimensional view and appreciation of the very real world around us, is the ultimate and final product of all of the processes which result in vision. It is the epitome, the ultimate manifestation, the apex of the visual process, the crowning glory, so to speak.

We now go one more step into that glorification. We think that process of creating in the brain the 3 dimensional world we live in, is the very foundation for **egocentric localization**, for which there is a "space center" in the brain, not yet precisely localized. But that is the place where all 3-D information our stereoscopic vision records is stored in an orderly fashion that creates the world we actually perceive and live in.

Now you can see why we think that binocular vision and stereoscopic vision (and normal stereoacuity) is so very important to us (and to all inhabitants of this world). It creates the mental imagery of the actual world we live in day to day, minute by minute. That is who we are and where we are, full time.

And that is why the personal stories on the three prior pages are important and worth publishing, yet again, in the case of Stereo Sue, for her so perceptive conclusions.

And there is a third case to be added here, which created for the editor the

foregoing hypothesis. Again personal and is based on the editor and his spouse, orthoptist Judy, who effectively manages this publication since its inception

She is sort of missing her egocentric localization. She has as long as she can remember. North, South, East and West and compass directions have no meaning, no comprehensibility to her. She is the opposite of one of those trace back GPS (Global-monitoring position systems). She cannot do that at all on her own.

She let me do all the driving for us initially for several years, then took over the wheel and has never given it up since then, because my driving makes her sick. But I have to tell her exactly where to drive all the time out of town, even when she has driven the same route a number of times and I must instruct her very specifically: "see that traffic light ahead?, turn right there." No navigation system instructions like "turn north in 400 yards, a quarter of a mile." No "at the intersection turn toward Denver." She never knows which direction Denver is...

As a child she was frequently car-sick she says. When she was 12 years old she suffered a terrible indoor accident when she tripped and crashed her face and broke her zygoma against stacked church tables. I think that her lack of egocentric localization may have contributed because she has broken bones in unusual accidents since then. Suggesting to me, anyway, an inadequate

connection to her environment, a lack of self protection. She never learned to fall in a protective manner, as in “drop and roll.” She refuses to try. I connect that to her localization problem. In childhood she was treated by one of the very best “pediatric ophthalmologists” at the time at a world famous children’s hospital for her myopic anisometropia. Unfortunately, her eyes changed and her refraction went out of binocular balance. After she left his care, she lost her binocularity and her stereopsis and depth perception totally but didn’t know it at all. Then she became an orthoptic student and her problem was discovered and with proper binocular balance restored, she regained her binocular vision and got her stereoacuity back to normal. Was that good? Yes, but to my surprise, it was hardly appreciated at all.

I wonder if there is a connection between all that and her lack of egocentric localization.(is it possible that one might be the cause of the other?)

Stereo Sue’s excitement over experiencing stereoscopic depth perception for the first time must have been gratifying for her doctors. I wonder if she was so thrilled - because she is married to an astronaut who experiences extraterrestrial egocentric re-localization, REGULARLY ! With the opening of her 3D world and probably also her egocentric localization she finally knows where he is all the time !!!!! (and whose wife doesn’t want to know exactly that about her spouse! Just yesterday, mine lost me momentarily when I stepped outside on our upper deck to cool off. I didn’t tell her and when she wanted me she started calling my name but I couldn’t hear her out there. She was very unhappy about that...)

Speaking of orthoptists....

They are having their quadrennial meeting in Toronto in 6 months.... (see their ad on page 245) that’s the IOA: International Orthoptic Association, with whom we recently responded to an invitation to explore some of their needs, but they evaporated.

The late great Marshall Parks sort of destroyed orthoptics as a real free standing profession (along with “ocular motility”, the subspecialty, too). He grew up with optometry establishing a competition to ophthalmology and opposed orthoptists because he feared they would do likewise. “Strabismologists” (or strabologists as we prefer) were the main employers and needers of orthoptic services but they have all been eliminated and converted by Parks and the medical market to pediatric ophthalmologists, (including yours truly and even my mentor, Gunter von Noorden....) forcing the orthoptists, if they wished a paying job, to become pediatric ophthalmologist physician extenders, like oph. techs and oph. Medical techs.

In The Mission Statement of the I O A, 2001, the only statement that we could find now relating to the role of the orthoptist with regard to binocular vision, per se, was that the orthoptist “treats the double vision where possible” *and that’s it ,all of it, for all aspects of binocular vision. --Not a word about “binocular vision”, or stereoscopic vision, or fusion, or vergences or any of that old stuff*]. But there is now a long list of non-orthoptic tasks they can ?officially do.

It’s sad. They are who we need to treat all those strabismus cases who don’t get binocular vision from their eye muscle surgery. There’s lots of them. *-per*

EDITORIAL: EYE CANDY WORLD: Don't Think, EMOTE! STRABOLOGY Surgery for Nystagmus; Slip? Trypan Blue; Globe Fixes.

"Substance" is gone from this world. It doesn't count anymore. Now all that counts is images, first impressions. Twitter celebrates the first few ill considered knee jerk reactions in your brain. Everything is just "eye candy" now or Demagoguery. And Relabeling is de rigueur. It's All "Show", no "go" needed.

Isn't this exactly the opposite world from what we pursue as doctors and scientists? The eye candy world is totally based on first emotions, not knowledge or facts. Emotions are the rawest part of life—they are for those first and second objectives: survive and reproduce. And I can't stand to watch sports events anymore- all the reporters want from the participants is "HOW DOES OR DID IT FEEL to... you fill in the blank...

Thinking is now totally illegal.

Maybe we should start all our patient exchanges now with, "how does it feel to be sick?" or just "not normal!" Maybe we should just end our treatment with a good dose of empathy: "Yes, I know exactly how you feel and I feel your pain" "Let's skip any treatment since that is not emotional stuff..."

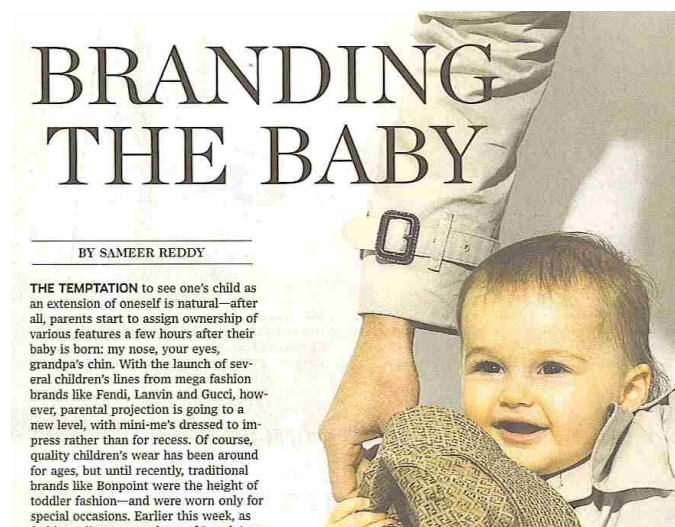Speaking of raw emotion, we all know what the "oldest profession" is. We always say yes and yes, and the SECOND oldest profession? Advertising... Came about to SELL the first profession... and since then to sell everything else.

AND advertising DOES WORK WHEN REPRODUCTION OF THE SPECIES IS JOB ONE THRU' TEN. LOOK, WE NOW HAVE 7 BILLION

HUMANS AND WE DOMINATE THE WORLD WE LIVE IN.... JOB DONE!

Now it is all looking and being "cool".

Branding everything, including one's self, is all the rage now including "branding the baby: See figure from Wall Street Journal.



Social networking is just "branding" and advertising yourself. For young people now, YOUR SELF CREATED PORTRAIT ON FACEBOOK IS THE MOST IMPORTANT THING IN LIFE: HOW MANY "FRIENDS" DO WE HAVE???

IT IS "CLICKS" (I.E., "LOOKS" AND "LIKES") THAT COUNT- NOT SALES OR EVEN WHO (BUT to HIT "FRIENDS" BACK AGAIN to fluff their numbers.

RESULTS? It is NOW, MORE THAN EVER, TRULY, truly "caveat emptor" when it comes to results everywhere. COLLEGE DEGREES ARE WORTH NEXT TO NOTHING ANYMORE. Too easy. And the smallest error or hesitation you may make in

paying your bills will be held forever against your credit rating..... no excuses please!!!!!!

So we too are trying to rebrand our baby, the science of binocular vision and strabismus, by calling it "strabology" a much more marketable name. Costenbader and Parks, God Bless and rest their souls, took ours away from us in a huge marketing ploy by rebranding us "pediatric", following all pediatric subspecialties in vogue. That forced all interested only in strabismus to become a pediatrician first. Well, let's undo that. Our P.O. meetings are too dammed big now anyway.... remember EYE and ENT split?

Yea "strabology"! The shorter term is easier to hear, say and understand. See ,too, our editorials in last two issues of *BV&SQ*.....

In this issue: Letters: First: Suzanne Veronneau Troutman on the etymology of strabology... then Facciani and Kraft, on the latter's publication here on Duane's .

Then two letters about strabismus treatment (surgery and goals). And my editorial on that topic. Then:

Binocular Ocular Motility: Breaking with the Past: How Understanding Dynamic Ocular Motor Control and Central Nervous System Plasticity Promote Novel Discovery and [Surgical] Therapy of Nystagmus. Hertle RW. Binocul Vis Strabolog Q Simms-Romano's 2011; 26(4):210-221

This is Dr. Hertle's paper from the Zoo program at San Diego last Spring, which he used to bring us all up to date on strabismus surgery's usefulness in nystagmus treatment. It is!.. even if you can't prove an improvement in visual acuity. He says his problem is convincing us that strabismus surgery does help nystagmus vision because:

"I would guess there would be a consensus objection from eye care professionals if the expected primary purpose of strabismus surgery suddenly changed from an ocular motor goal (binocular alignment) to that of improving visual acuity? ***But he is proposing just that is true for nystagmus...***

(Coincidentally we feel too many quit treating binocular vision too early but for another reason: they just don't care about binocular vision.) (See also prior editorial....)

Editing Hertle: First, we had to add to his title the term "nystagmus" to facilitate retrieval by as broad an audience as possible. But then we thought: add a broader term to start, to orient the reader about the subject...

So where does nystagmus fall, other than neuro-ophthalmology? "Ocular Motor Control" appears in the title, so it is within "ocular motility", but that term is so broad. One eye or two? Movement...vision?. More about this later (below) but we thought attaching "binocular" to it a good idea. The redundancy of "-ocular" is natural.

The Use of Trypan Blue Dye for Strabismus Reoperations, Surgery Complications, and Especially for the Identification and Recovery of a "Slipped" or "Lost" Extraocular Muscle. Shokida F, Aguirre R, Croxatto O. Binocul Vis Strabolog Q Simms-Romano's. 2011; 26(4):222-229

A wonderfully good idea and it works wonderfully easily and well. Beautifully illustrated! Thank you!

With Strabology "Patron Saint"'s Assistance on this paper (Arthur Jampolsky) it was easy to expedite its publication. But as soon as we started to edit and expand the title, as we always do, to insure it comes to the attention of the widest and best audience,

we found ourselves again wrestling with slang and jargon.

Words are such weapons. Not just in politics but also in science where they can be used, as in politics, to misdirect attention and thought, to attract attention, to entertain. The fact that we claim to be science and therefore our words should be as accurate and precise as possible is forgotten. But we are all still, it seems, more like children just seeking to be the focus of attention.

So in the case of this paper, we were diverted at the start by the term "slipped muscle", a now well established, but horrible example of, this unscientific compulsion to be cute and trick at the same time. These authors did not invent it. It has been around for a while, since at least 1974 in Pub Med.

We attacked its misuse in a an editorial just 8 years ago in issue 19(3)137-8.

In Pub Med, only Alan Scott seemed to have the courage to call it: "Disinserted" (1975). It should be "**Strabismus Surgery Complication: Suturing/suture material failure suspected.**" or "**Failure of repair of elective surgical wound(ing)**"

(Ed Note: This term, "slipped" muscle, is used as a **cover-up**: to shift the cause and any fault and blame for what is a surgical complication or frank error on the part of the surgeon to an inanimate and defenseless third party: the extraocular muscle of the patient. **WE are shifting the blame to the patient!** This redirection of blame through intentional semantic misuse is common today in our highly litigious society and there are many examples, especially in government where political guilt must be totally avoided, as well as in medicine where lawsuits must be avoided. **Here, a surgeon has SLIPPED, NOT the muscle !** (Think that instead...)

Periosteal Flap Fixation of the Globe for Surgical Treatment of Severe Restrictive Strabismus. Ahmed R, Coats DK, Yen MT. Binocul Vis Strabolog Q Simms-Romano's 2011; 26(4):230-235

Globe Fixation with Homologous Temporalis Fascia Transplant for Treatment of Restrictive Esotropia Strabismus: An Interventional Case Report and Review of the Literature. Bagheri A, Efrfanian-Salim R, Salour, Yazdani S. Binocul Vis Strabolog Q Simms-Romano's 2011; 26(4):236-242

In This Issue, by coincidence we have not one but two papers on globe fixation for severe restrictive strabismus, both providing excellent help in these most difficult challenges with heroic techniques.

Three papers, Hertle and these two, in this issue, have a major nosology problem.

There are two major subtypes of strabismus / ocular motility problems not previously specified: "Monocular" versus "binocular" We do somewhat recognize this in the classification of strabismus into "comitant" (usually non paretic) and "incomitant" (usually paretic or anatomical or mechanical).

For cases like these we need to separate (primarily) binocular ocular motility problems/components from (primarily) monocular ocular motility problems/factors and rank them in order of attention and action because very different principles may be involved in their resolutions, and especially in evaluating the outcome of our attempts to do so.... Personally I strongly recommend my Stage III intraoperative (strabometry and suture) adjustment (Proc VI ISA, MacMillan Press, London 1990; 473-478)

Have a good holiday - per

Original Scientific Article

Binocular Ocular Motility: Breaking With The Past: How Understanding Dynamic Ocular Motor Control and Central Nervous System Plasticity Promote Novel Discovery and Therapy of Nystagmus

RICHARD W. HERTLE, M.D.

*from The Children's Vision Center, Akron Children's Hospital, Akron, Ohio and
The Northeastern Ohio Universities College of Medicine, Rootstown, Ohio, USA*

ABSTRACT: Introduction: The lure of studying the ocular motor system stems from its anatomic and physiological accessibility, ease of measurement and analysis of function, as well as the promise of providing a direct window into the brain. There is an increasing body of knowledge on how the brain responds to peripheral eye muscle manipulation (surgery/medications/denervation/genetic therapy). Investigations in both animals and humans have established that plasticity within the brain occurs after peripheral neuromuscular (medical/surgical) disruption and repair.

Purpose: This paper will review and summarize neurophysiological concepts resulting from recent investigations of the ocular motor system and treatment of involuntary oscillations such as nystagmus.

Methods: Review of both a multidisciplinary literature and the author's 25 years experience evaluating, treating and investigating the ocular motor system.

Conclusions: The ocular motor system in man is a continuously controlled, malleable brain-eye system, which is genetically programmed, environmentally modified and contains powerful reparative processes. It begins during development, extends throughout life and is subject to external manipulation in both health and disease.

These ideas challenge the historically significant axiom, i.e., that there is eventual (and a final maturing to an end state) "hard-wiring" of much of both the ocular motor and afferent visual systems. Rather, they now are shown to maintain some degree of plasticity **throughout life**.

Received for consideration and accepted for publication May 29, 2011

Presented, in part, at "Pediatric Ophthalmology At The Zoo", (a Pre-American Association for Pediatric Ophthalmology and Strabismus Meeting), San Diego, California, March 30, 2011

*Correspondence: Richard W. Hertle MD rhertle@chmca.org
300 Locust Street, Suite 490, Akron OH, 44302-1804*

Creativity, the foundation of discovery, is the ability to transcend traditional ideas, rules, patterns and relationships and to create meaningful new ideas, forms, methods or interpretations.

This process can only be accomplished in a mind-set Carson calls “absorb” during which an individual’s mental state suspends strict criticism thus eliminating restrictions on one’s ability to take in knowledge (1). Critical thinking is as important a part of science as its technology, but, like technology, has its place in the process. At the beginning of every discovery, piece of art, building, or mechanical device there exists the “idea”, or “*mental image*”, of that. The process of mental imagery resulting as part of the creative process can only be realized by initially removing the constricting effect of “total” criticism. Likewise the absorption of new ideas and hypotheses requires an initial suspension of criticism, after which a more thorough and unbiased assessment of the idea is possible.

It is hoped that the reader will enter into a “absorb brain-set” when reading the following concepts describing a dynamic brain-eye system (1).

The idea of an *interactive* central and peripheral nervous system is not new. *Vesalius*, the great Belgian physician said, “The nerves may be considered as the diligent servants and messengers of the brain” (2). Leonardo da Vinci described the “*imprensiva*”, a brain structure that mediates between sense organs (such as the eye) and the *senso commune* (common sense, part where all senses meet) (3). Indeed, the basic idea of “afferent” and “efferent” components within the nervous system is centuries old. In the visual system this conceptual approach to

visual and other nervous function is not quite so simple as exists in the spinal axis. In addition to classic spinal afferent pathways of pain, temperature and touch, the central afferents contain also contain more complex systems such as the parallel visual sensations and ocular motor proprioception. Classic efferent pathways in the visual system include, voluntary and involuntary neuromuscular and glandular systems. Less well-known efferent pathways include neurotrophic and efference copy systems (4).

We are just beginning to understand the molecular genetics, environmental/-developmental modulation and physiological intersystem communications that take place during embryonic and early post-natal development of the nervous system. It is probable that disruption of genetics, development and systems communication alone, or in combination, results in much of the pathology we see in the ocular motor system. Studying eye movement physiology, development and anomalous function has resulted in a deep and dramatic understanding of many brain functions.

A simplistic view of the infranuclear ocular motor system, depicted by the 19th century ophthalmotrope (see **Figure 1, TOP next page**), has been replaced with the pioneering work of Miller and Demer on the extraocular muscle active pulley hypothesis resulting in novel structure-function relationships (see **Figure 2, Bottom, next page**) (5).

In addition, the supranuclear ocular motor system consists of several (smooth pursuit, vergence, saccades, optokinetic, vestibular) interconnected and synergistic subsystems each responsible for a particular class of eye movements.

Figure 1 (Hertle):
Ophthalmotrope. (Ruede, 1858;
Helmholtz, 1887) *The most sophisticated ocular motor model of the nineteenth century was made by Wundt in Heidelberg (pictured here), which used physiological variables as muscle forces, represented by springs and weights. Remarkable in his analysis is that the spring constants of his model muscles were directly related to the cross-sectional area of the muscle and inversely related to the length of the muscle, as determined in post-mortem studies.*

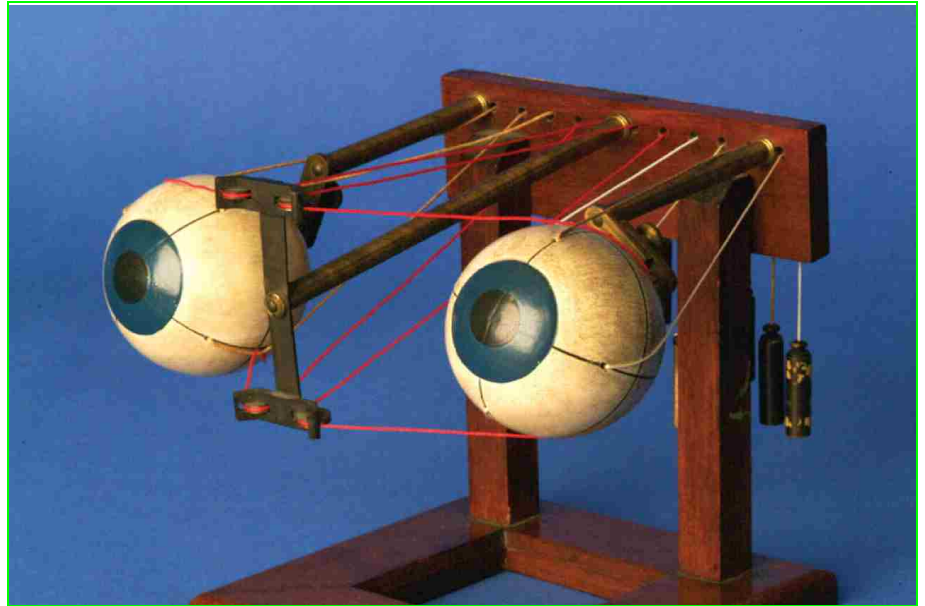
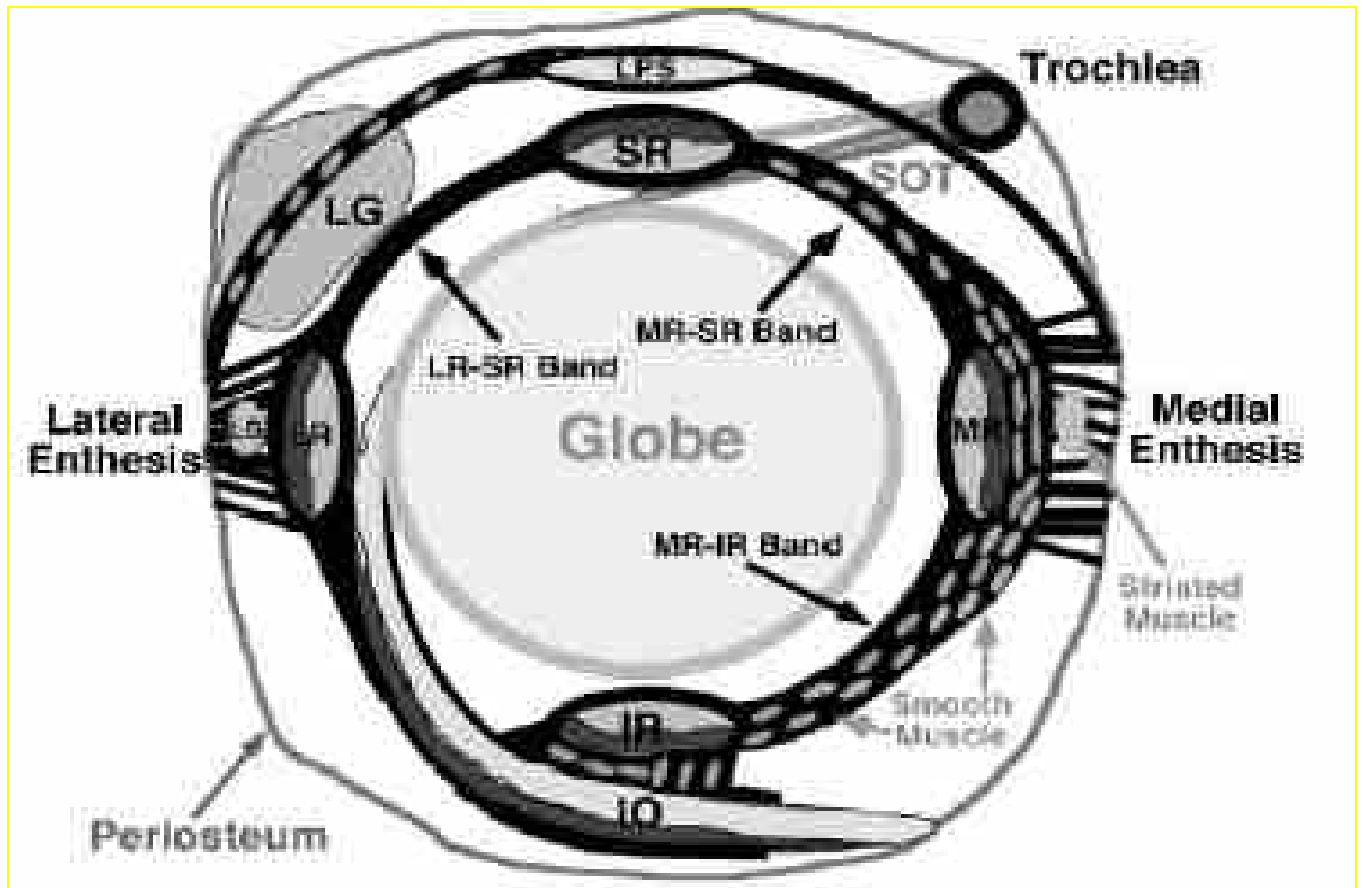


Figure 2 (Hertle): Active Muscle Pulley Hypothesis . *The active-pulley hypothesis proposes that a condensation of orbital layer of each rectus extraocular muscle (EOM) inserts on connective tissue, which constitutes a pulley serving as the functional origin of the rectus EOM, and that this pulley makes coordinated, gaze-related translations along the EOM axis to implement a linear ocular motor plan. (Demer JL. Current concepts of mechanical and neural factors in ocular motility. Curr Opin Neurol 2006;19:4-13.)*

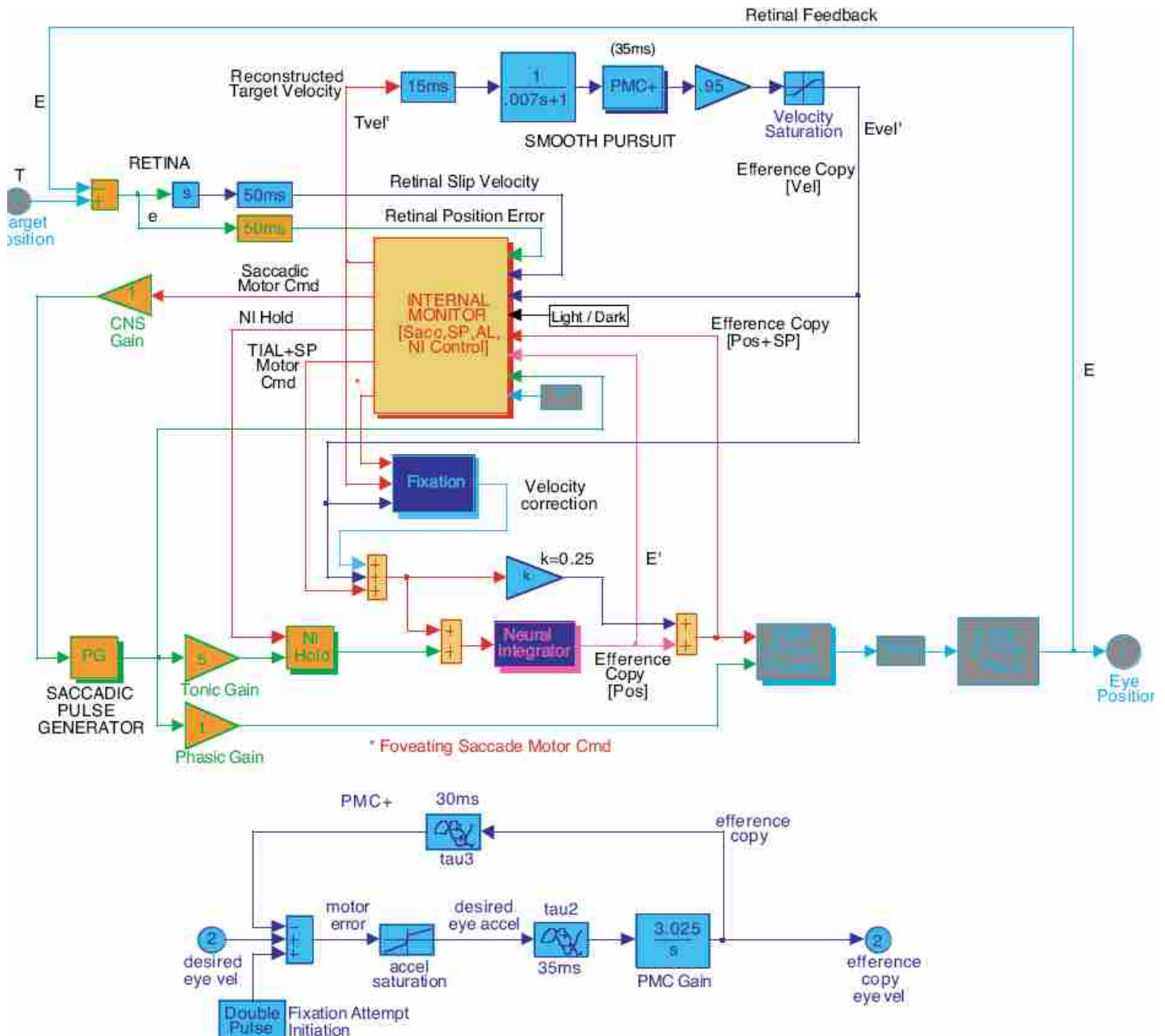


The study of the anatomy, physiology, and pathophysiology of oculomotor control has benefitted more from control systems theory than many other branches of motor control. Investigators in areas ranging from biological control systems and neurological diagnosis to applications in advertising and flight simulation find that eye movements provide clear indicators of what a sensory-motor system can accomplish and what is happening in a discretely communicating connection between the peripheral and central

nervous system (6).

Control theory emerged from the military engineering of World War II as a tool for understanding the nature of biological systems. It was popularized by Wiener's books on cybernetics, and produced a newly developing community, called bioengineering, which began to look for suitable problems, finding one in quantitative application of linear control theory to biology (6).

Figure 3 below: SEE next page....



ABOVE, foot of prior page: Figure 3 (Hertle): Unifying Model Describing the Waveforms of Infantile Nystagmus Syndrome (INS). The robust simulations of accurate ocular motor system behavior in the presence of diverse INS waveforms demonstrate that they can all be generated with this model and are due to a loss of pursuit-system damping. (Dell'Osso LF. Biologically relevant models of infantile nystagmus syndrome: the requirement for behavioral ocular motor system models. *Semin Ophthalmol* 2006;21:71-7.)

Early interest in eye movement research resulted in brain modeling, which came from surprising places, including the defense laboratories, interested in *where a gunner might look next*. This approach has resulted in many examples of computer models (**Figure 3, supra, foot of prior page**) of the normal ocular motor system that

simulates saccadic dysfunctions, gaze-evoked nystagmus, myasthenia gravis and the waveforms of nystagmus in infancy and childhood (6).

Eye-movement recordings (**see Figure 4, directly below**) have become the method(s) of choice in a wide (*continued*)

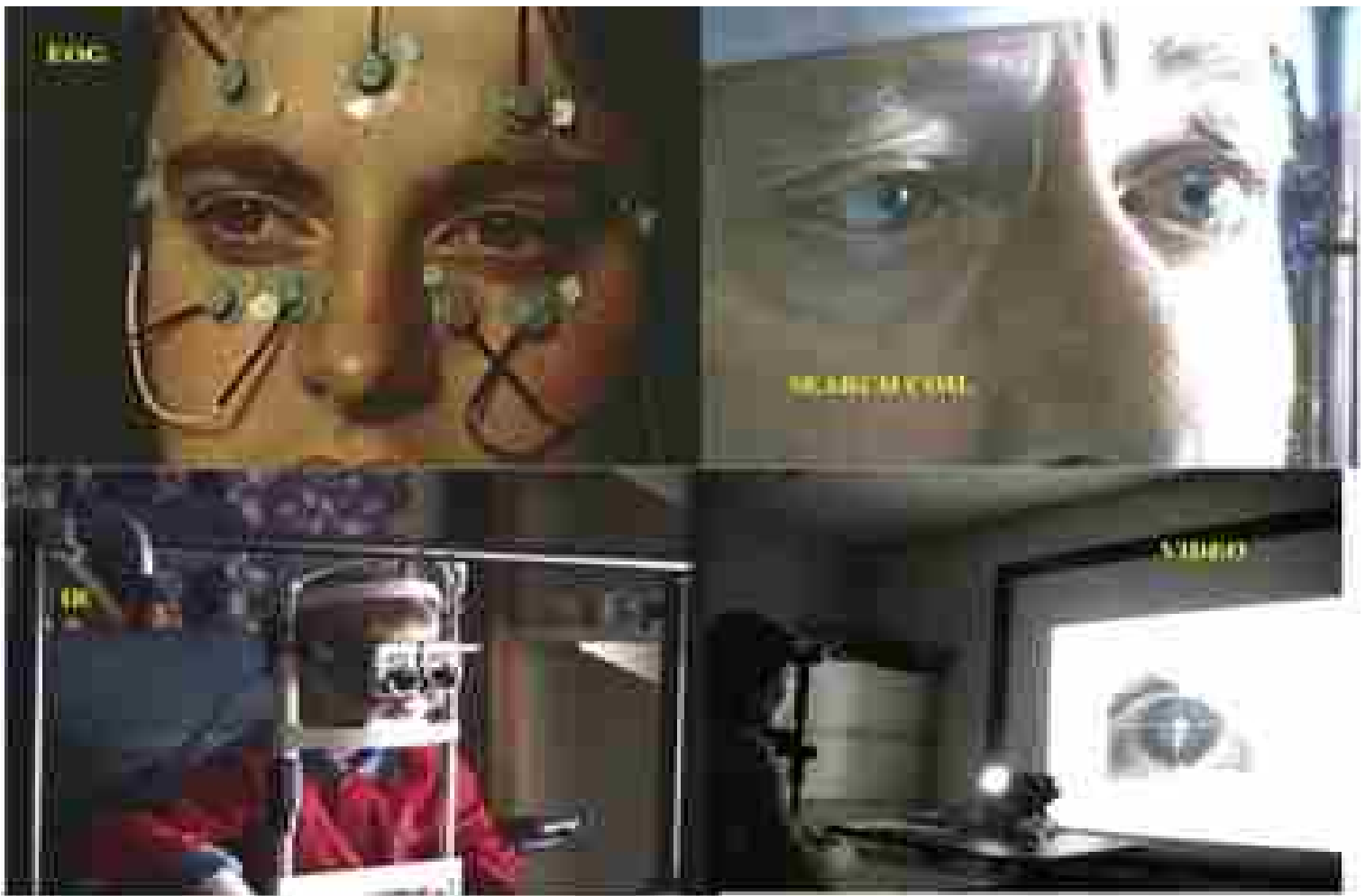

Figure 4 (Hertle): Eye Movement Recording Techniques. The four most common recording techniques (electro-oculogram EOG, infrared reflection devices IR, scleral search coil, and video-oculography, VOG) vary according to spatial and temporal resolution, capability to record multiple degrees of eye freedom, setup complexity, system specific artifacts, and invasiveness.

variety of disciplines investigating how the ocular motor, vision sense, central nervous system cognition, memory, volition and emotion work. The four most common recording techniques, electro-oculogram (EOG), infrared reflection devices (IR), scleral search coil, and video-oculography, (VOG) vary according to spatial and temporal resolution, capability to record multiple degrees of eye freedom, setup complexity, system specific artifacts, and invasiveness.

Taxonomy and classifying ocular motor system disorders remains a constant challenge but without a consistent system of terminology the complex methodologies of modern clinical science have no starting point. In 2001, 22 of the nation's most experienced clinical and basic science investigators in the diagnosis, treatment, and etiology of eye movement abnormalities and strabismus from various disciplines met for a 2-day workshop on the Classification of Eye Movement Abnormalities and Strabismus (CEMAS) at the National Eye Institute, National Institutes of Health Campus, Bethesda, MD (7). The work of the CEMAS group over the ensuing year resulted in a document that provides a foundation for the systematic classification of primary eye movement abnormalities and strabismus. This document also introduced a more specific, **non-eponymic** nomenclature.

The complexity of neural development is no where better manifested than in the coordination and communication that exists between the developing ocular motor and visual afferent systems, as a result of errors in that process of communication we are now beginning to understand the true pathophysiology of ocular motor disturbances such as infantile nystagmus syndrome (old "congenital nystagmus") (**Figure 5, right**).

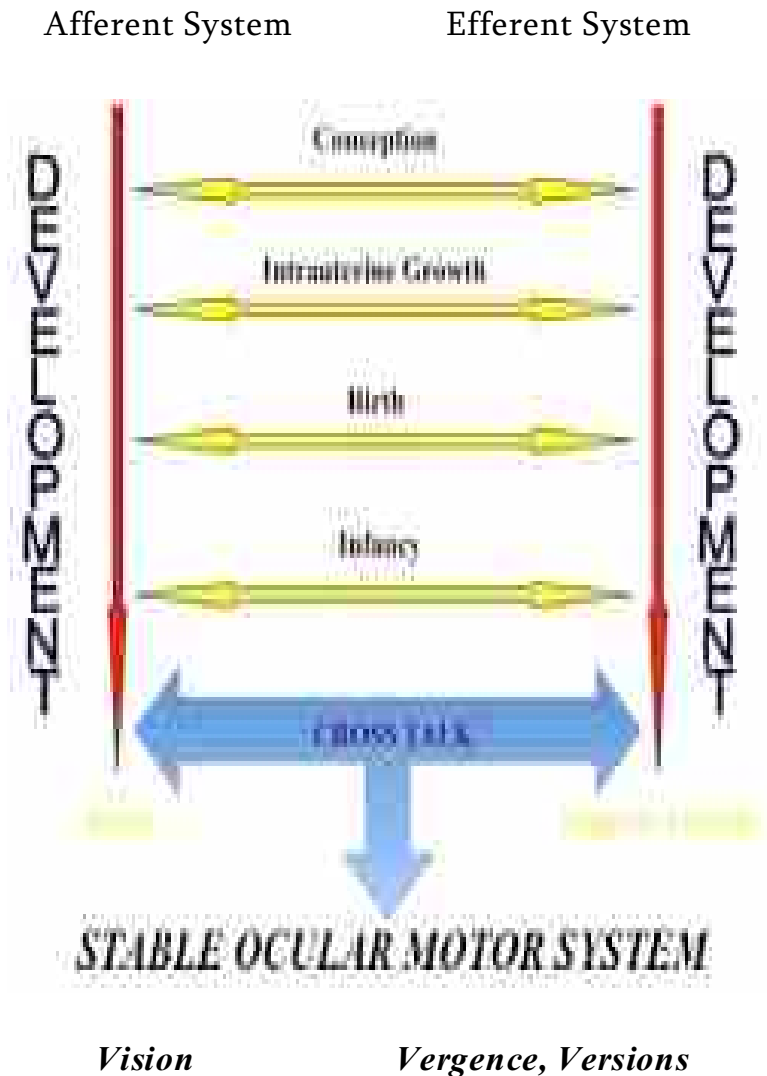


Figure 5 (Hertle): Model of Parallel Pathway Development in the Visual System. Ocular motor system calibration is an active process that may start in utero and continue at least through early infancy. Sensory-system development is a parallel visual process that continues to develop through the first decade of life. Documented connections between parallel visual processes (cross-talk) that modify, instruct, and coordinate these systems, result in smooth and coordinated function. Ocular motor instability may result from abnormal cross-talk from a defective sensory system to the developing motor system at any time during the motor system's sensitive period.

Tychsen et. al. have elegantly shown us how disturbances in these communicative processes at the level of the visual cortex contribute to the genesis of fusion mal-development nystagmus syndrome (old “latent nystagmus”) (8).

No longer can visual scientists or clinicians ignore the complex interrelationship of the developing visual afferent and visual motor systems and as a consequence need to evaluate both if there is a developmental disorder in either. Most, if not all, of the technologies for evaluation of the afferent visual system are feasible for clinical use. This includes behavioral testing of acuity in infants, visual evoked responses, electroretinography, color, contrast sensitivity and visual field testing. There is now also important information to be obtained from optical coherence tomography (**Figure 6, right,)** (9).

The complex combination of structural and developmental visual sensory and visual motor abnormalities in infants and children with nystagmus results in varied and multiple effects on visual system functioning, these include decreased spatial acuity, contrast sensitivity, color, motion perception, dark adaptation, functional visual field/space, visual recognition time and a high incidence of ametropia, binocular dysfunction and amblyopia (9, 10). There may be a form of amblyopia unique to the developing visual system of eyes in constant motion which we have labeled “motion amblyopia,” the complete visual consequences of which are yet to be described. The importance of the how treating the developing system affects both the afferent and efferent systems was

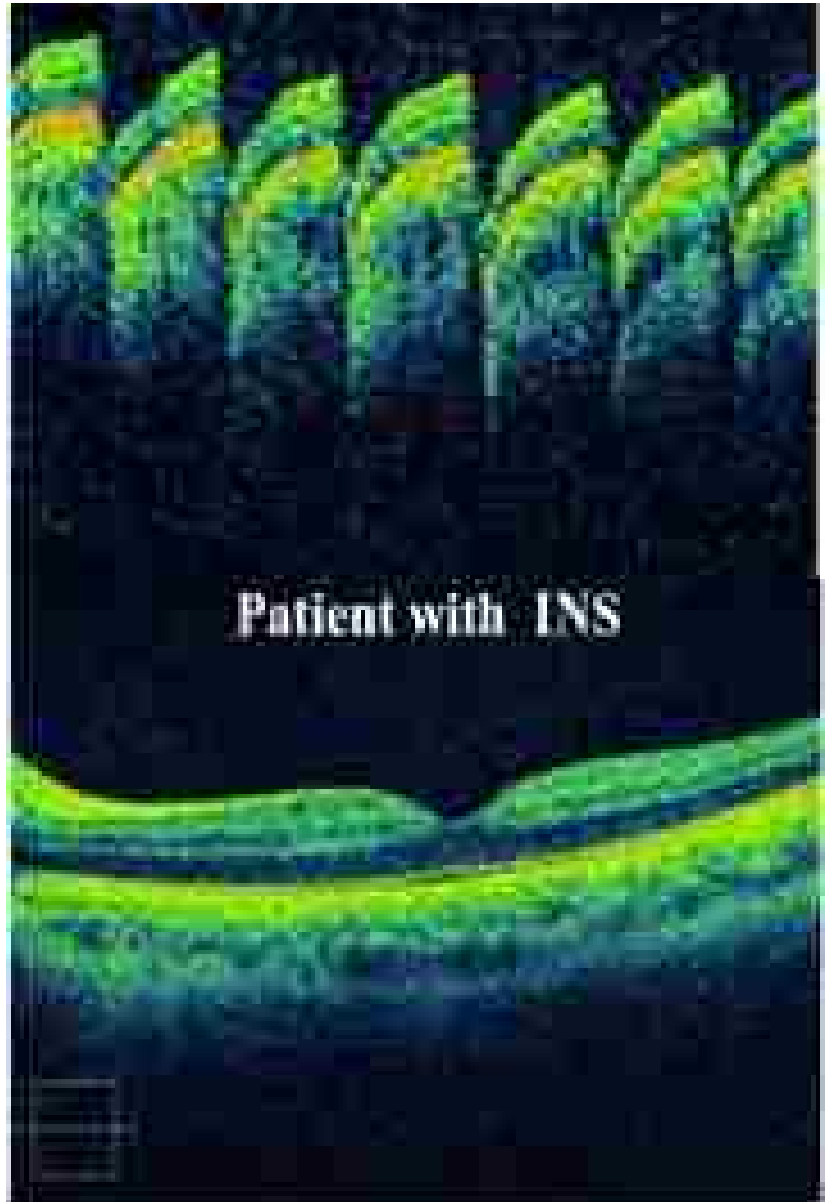


Figure 6 (Hertle): Spectral Domain Optical Coherence Tomography (SD-OCT). Images demonstrating normal foveal morphology (top) and possibility of using SD-OCT to evaluate the ocular oscillation in a patient with infantile nystagmus syndrome, (bottom). (Cronin TH, Hertle RW, Ishikawa H, Schuman JS. Spectral domain optical coherence tomography for detection of foveal morphology in patients with nystagmus. *J AAPOS* 2009;13:563-6.)

shown in an animal model of developmental retinal disease, with associated infantile nystagmus, when, after treating the sensory system with gene transfer therapy, the ocular motor system was also improved. (11, 12).

Subjective perception of black letters on a white screen is not a good measure of ocular motor function.

Unfortunately, the reporting of visual acuity has become a necessary outcome measure when reporting results of interventional clinical trials attempting to improve the ocular motor oscillation in patients with nystagmus. While there is no doubt of the importance of vision and its primary measure (visual acuity), absolute reliance on its improvement as a judgment of success of eye muscle surgery/medications for nystagmus places a large burden on nystagmus treatments, the primary goal of which is to improve the ocular motor system.

I would guess there would be a consensus objection from eye care professionals if the expected primary purpose of strabismus surgery suddenly changed from an ocular motor goal (binocular alignment) to that of improving visual acuity? More accurate measures of ocular motor and visual function in patients with nystagmus are, foveation time, waveform type, expanded nystagmus acuity function, null zone depth/breadth, periodicity, visual recognition time, vision as a function of gaze, motion detection, contrast sensitivity, visual-vestibular function and visual quality of life questionnaire (13, 14).

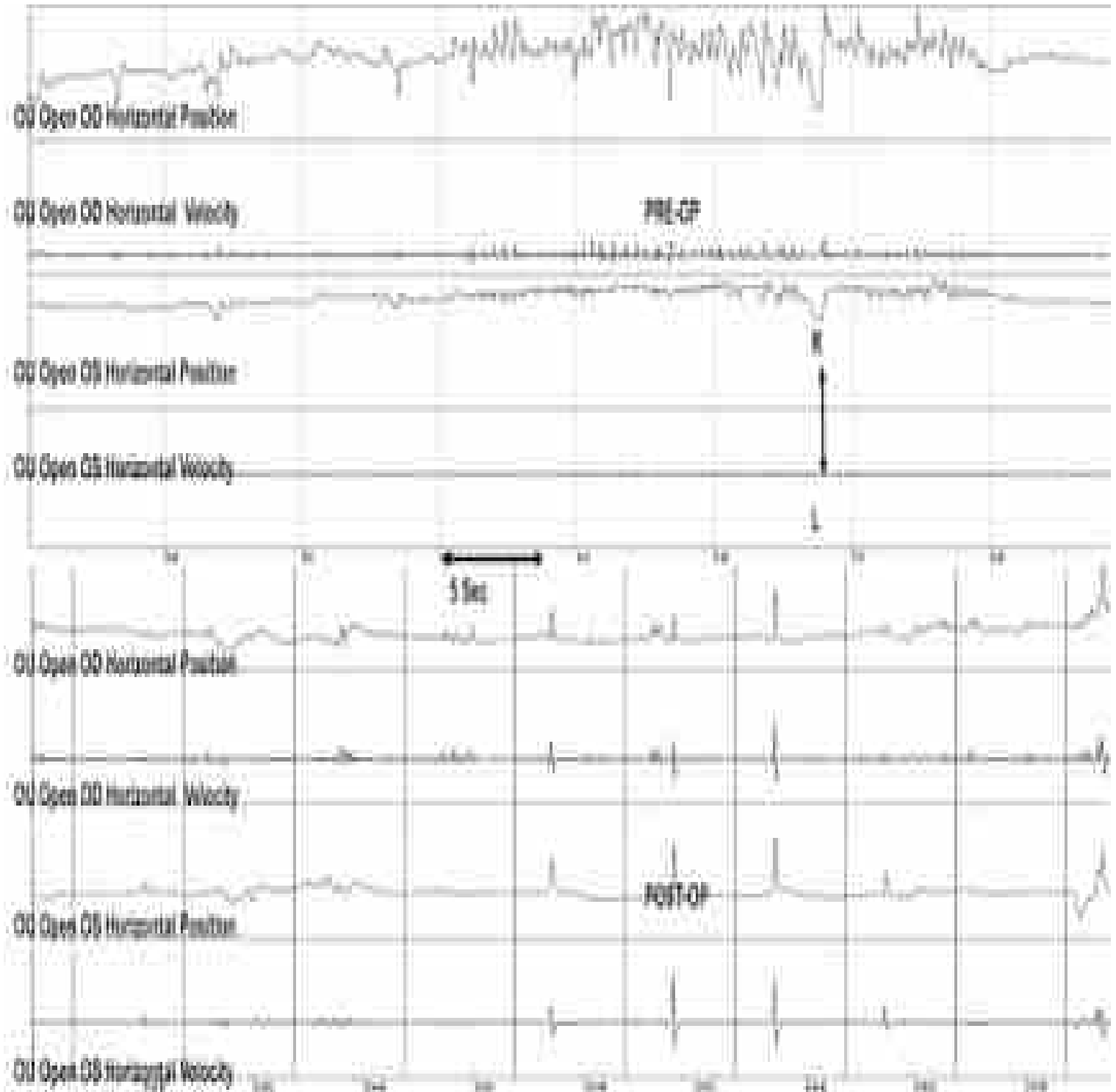
It was not until an animal model of infantile nystagmus syndrome (INS) was found in the 90's that the observations by

Anderson in 1959 and Dell'Osso and Flynn in the late 70's that nystagmus and vision improve after eye muscle surgery could be further tested (15,16). Since that time numerous clinical trials, observational reports and basic science anatomy and physiological studies have suggested that surgical perturbation of the peripheral ocular motor system results in profound and persistent changes in central functioning (17-27). **Figure 7, Next Page**, shows an example of the electrophysiological effects of eye muscle surgery on the ocular oscillation in the null zone of INS in a patient with oculo-cutaneous albinism.

Visual system measures including, acuity, contrast sensitivity, motion detection, recognition time, binocularity, null zone breadth-depth and a visual sense of well being, have been shown to improve after eye muscle surgery in patients with INS. The common clinical perception is that eye muscle surgery in patients with INS has, as its only purpose, to move the alignment of the eyes and/or head thus improving strabismus and/or centralize the INS null position. In fact, what happens is a physiologically measurable change in the nystagmus oscillation resulting in a broadening and deepening of the null zone.

Recently discovered peripheral afferent neuroanatomy with its central ocular motor connections may be the mechanism by which peripheral disruptions initiate central changes (10). Plasticity following peripheral nerve transection has been demonstrated throughout the neuroaxis in animal models of nerve injury. Human brain imaging studies have corroborated the findings from animal models

Figure 7 (Hertle): Eye Movement Recordings. This figure demonstrates the electrophysiological effects before and after eye muscle surgery on the ocular oscillations in the null position of a patient with INS and oculo-cutaneous albinism. (OU = both eyes, OD = right eye, OS = left eye, PRE-OP = preoperatively, POST-OP = post operatively, sec = seconds R = Rightward, L = Leftward)\



with the identification of altered functional MRI activation maps due to spinal cord in-

jury, amputation, toe-to-thumb transfer, and in patients with carpal tunnel (Figure 8,

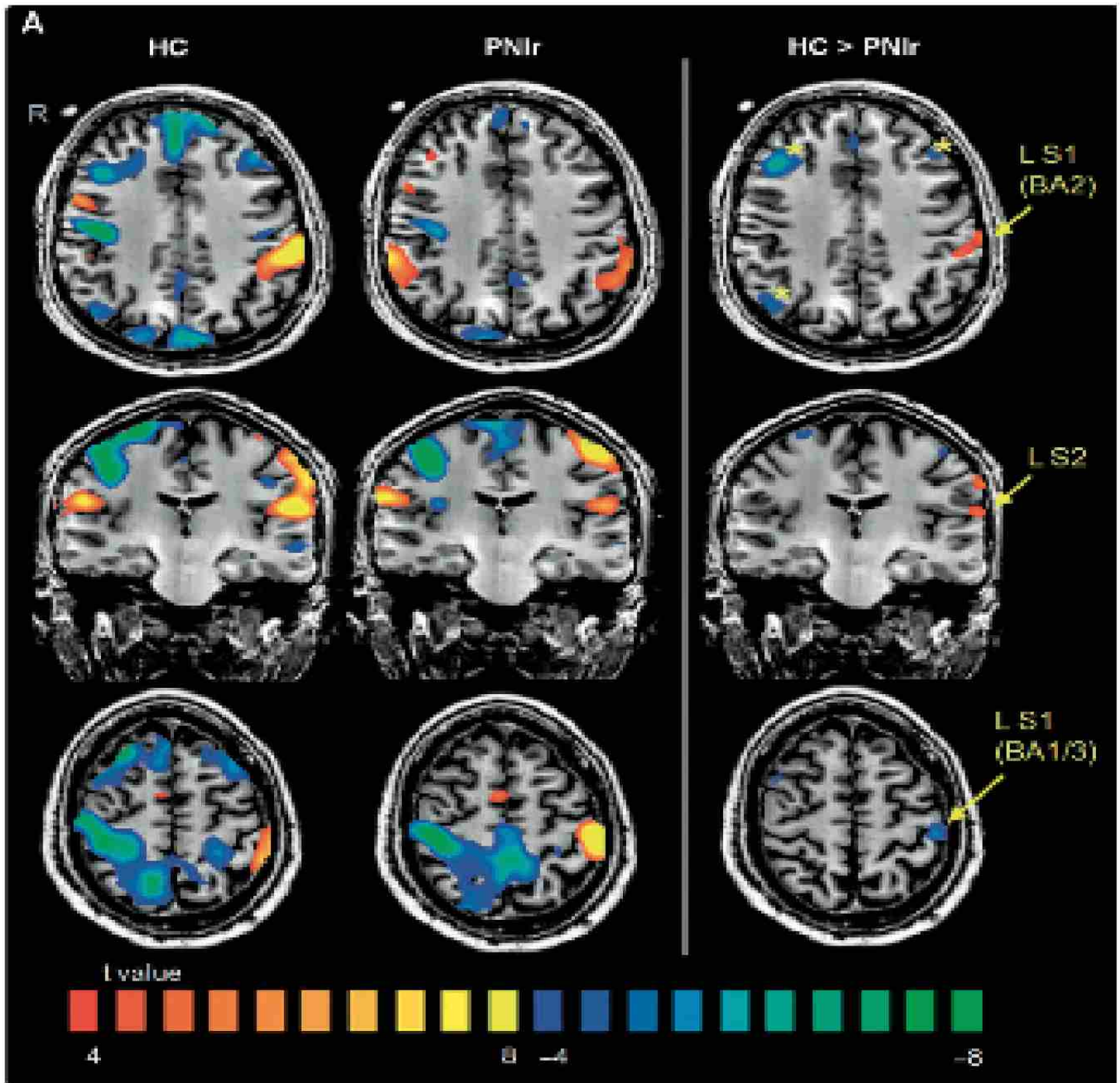


Figure 8 (Hertle): BOLD Response To Vibrotactile Stimulus Applied To Transected Nerve. The left first and second columns display regions of significant activation/deactivation (compared to rest) in healthy controls (HC) and PNIr, respectively. Bar; third column displays significant group differences with contrast HC>PNIr. Event-related averages demonstrated that HC activate lateral S1 (BA 2) (BA=Brodmann area; BOLD=blood oxygen level dependent; fMRI =functional magnetic resonance imaging; PNIr=peripheral nerve transection and surgical repair; S1=primary somatosensory cortex; S2=secondary somatosensory cortex). (Brain 2009: 132; 3122–3133)

above,) (28). There is also functional plasticity in several cortical areas following upper limb peripheral nerve transection and surgical repair.

Until recently, most neuroscientists believed that the adult brain is hard-wired and largely incapable of reorganization. The only areas of the brain where some reorganization might occur would be those involved in learning and skill acquisition. However, over the past two decades, it has been conclusively established that even primary sensory areas of the brain are capable of reorganization in response to injuries or changes in patterns of peripheral stimulation. The mechanisms that facilitate functional plasticity are thought to include the immediate unmasking of pre-existing projections from adjacent cortical and subcortical levels, and long term sprouting of axons at multiple levels of the neuroaxis, including the primary somatosensory cortex (28).

There is accumulating evidence that EOM proprioceptive afferent signals are not only available to oculomotor and visual control structures, but they influence the processing of information in these structures, and may be involved in modifying visuomotor behavior after eye muscle surgery as well as oral and, possibly, topical medications.

REFERENCES

1. Carson S. Creative thinking and the brain. *Harv Health Lett* 2010;36:6.
2. Saban R. [The beginnings of physiology of the human brain, from antiquity to the Renaissance]. *Vesalius* 1999;5:41-7.
3. Berggren L. [Studies of vision by Leonardo da Vinci]. *Sven Med Tidskr* 2001;5:171-85.
4. Guerraz M, Bronstein AM. Ocular versus extraocular control of posture and equilibrium. *Neurophysiol Clin* 2008;38:391-8.
5. Demer JL. Current concepts of mechanical and neural factors in ocular motility. *Curr Opin Neurol* 2006;19:4-13.
6. Dell'Osso LF. Biologically relevant models of infantile nystagmus syndrome: the requirement for behavioral ocular motor system models. *Semin Ophthalmol* 2006;21:71-7.
7. CEMAS_Working_Group. A National Eye Institute Sponsored Workshop and Publication on The Classification Of Eye Movement Abnormalities and Strabismus (CEMAS). In: Richard W. Hertle MD, editor. The National Eye Institute Publications, www.nei.nih.gov; 2001 2/8/01-2/10/01; The National Institutes of Health, Bethesda, MD: The National Eye Institute, The National Institutes of Health; 2001. p. 1-57.
8. Tychsen L, Richards M, Wong A, Foeller P, Bradley D, Burkhalter A. The neural mechanism for Latent (fusion maldevelopment) nystagmus. *J Neuroophthalmol* 2010;30:276-83.
9. Cronin TH, Hertle RW, Ishikawa H, Schuman JS. Spectral domain optical coherence tomography for detection of foveal morphology in patients with nystagmus. *J AAPOS* 2009;13:563-6.
10. Hertle RW, Chan CC, Galita DA, Maybodi M, Crawford MA. Neuroanatomy of the extraocular muscle tendon enthesis in macaque, normal human, and patients with congenital nystagmus. *J Aapos* 2002;6:319-27.
11. Acland GM, Aguirre GD, Ray J, et al. Gene therapy restores vision in a canine model of childhood blindness. *Nat Genet* 2001;28:92-5.
12. Jacobs JB, Dell'Osso LF, Hertle RW, Acland GM, Bennett J. Eye movement recordings as an effectiveness indicator of gene therapy in RPE65-deficient canines: implications for the ocular motor system. *Invest Ophthalmol Vis Sci* 2006;47:2865-75.
13. Hertle RW. Does eye muscle surgery improve vision in patients with infantile Nystagmus syndrome? *Ophthalmology* 2009;116:1837-8.

14. Stevens DJ, Hertle RW. Relationships between visual acuity and anomalous head posture in patients with congenital nystagmus. *J Pediatr Ophthalmol Strabismus* 2003;40:259-64; quiz 97-8.
 15. Anderson JR. Causes and treatment of congenital eccentric nystagmus. *Br J Ophthalmol* 1953;37:267-81.
 16. Dell'Osso LF, Flynn JT. Congenital nystagmus surgery: a quantitative evaluation of the effects. *Arch Ophthalmol* 1979;97:462-9.
 17. Cooper EL, Sandall GS. Surgical treatment of congenital nystagmus. *Arch Ophthalmol* 1969;81:473-80.
 18. Parks MM. Symposium nystagmus. Congenital nystagmus surgery. *Am Orthop J* 1973;23:35-9.
 19. Nelson LB, Wagner RS, Harley RD. Congenital nystagmus surgery. *Int Ophthalmol Clin* 1985;25:133-8.
 20. Helveston EM, Ellis FD, Plager DA. Large recession of the horizontal recti for treatment of nystagmus. *Ophthalmology* 1991;98:1302-5.
 21. Dell'Osso LF, Hertle RW, Williams RW, Jacobs JB. A new surgery for congenital nystagmus: effects of tenotomy on an achiasmatic canine and the role of extraocular proprioception. *J AAPOS* 1999;3:166-82.
 22. Dell'Osso LF, Hertle RW, FitzGibbon EJ, Miles FA, Thompson D, Yang D. Preliminary results of performing the tenotomy procedure on adults with congenital nystagmus (CN) -- a gift from "man's best friend". In: Sharpe JA, ed. *Neuro-ophthalmology at the Beginning of the New Millennium*. Englewood: Medimond Medical Publications; 2000:101-5.
 23. Hertle RW, Dell'Osso LF, FitzGibbon EJ, Thompson D, Yang D, Mellow SD. Horizontal rectus tenotomy in patients with congenital nystagmus: results in 10 adults. *Ophthalmology* 2003;110:2097-105.
 24. Hertle RW, Dell'Osso LF, FitzGibbon EJ, Yang D, Mellow SD. Horizontal rectus muscle tenotomy in children with infantile nystagmus syndrome: a pilot study. *J Aapos* 2004;8:539-48.
 25. Gupta R, Sharma P, Menon V. A prospective clinical evaluation of augmented Anderson procedure for idiopathic infantile nystagmus. *J Aapos* 2006;10:312-7.
 26. Hertle RW, Yang D. Clinical and electrophysiological effects of extraocular muscle surgery on patients with Infantile Nystagmus Syndrome (INS). *Semin Ophthalmol* 2006;21:103-10.
 27. Wang ZI, Dell'Osso LF, Tomsak RL, Jacobs JB. Combining recessions (nystagmus and strabismus) with tenotomy improved visual function and decreased oscillopsia and diplopia in acquired downbeat nystagmus and in horizontal infantile nystagmus syndrome. *J AAPOS* 2007;11:135-41.
 28. Taylor KS, Anastakis DJ, Davis KD. Cutting your nerve changes your brain. *Brain* 2009;132:3122-33.
-

Original Scientific Article

The Use of Trypan Blue Dye for Strabismus Reoperations, Surgery Complications, and Especially for the Identification and Recovery of a "Slipped" or "Lost" Extraocular Muscle

FELISA SHOKIDA, M.D., RODOLFO AGUIRRE, M.D.,
and OSCAR CROXATTO, M.D.

*from the Departments of Pediatric Ophthalmology and Strabismus (Drs. Shokida and Aguirre)
and Ophthalmic Pathology (Dr. Croxatto), Hospital Italiano, Buenos Aires, Argentina*

ABSTRACT : Purpose: To evaluate trypan blue dye in strabismus surgery for tissue identification, to find the lowest optimal concentration, and to describe histological findings. in tissue so stained .

Methods: Trypan Blue dye 0.1% was serially diluted and tested by tissue staining at progressively different concentrations. Fifteen patients were studied using the dye.

Results: Trypan Blue 0.1% was the optimal concentration. Muscle, tendon and fibrotic tissues were easily identified and distinguished with the dye at this concentration. Such tissue identification was most useful and enhanced the performance of strabismus surgical operations, and especially in identifying and retrieving "slipped" or temporarily "lost" extraocular muscles.

Also a thin basement-like membrane surrounding the superior oblique muscle tendons was disclosed with PAS stain, suggesting the presence of glycosaminoglycans.

Conclusions: Trypan Blue 0.1% contrasts the different tissues, dying the muscle sheath, tendons and fibrotic tissues, but not staining the sclera and muscle fibers per se.

Received for consideration and accepted for publication September 23, 2011.

Acknowledgments: The authors thank Dr. Arthur Jampolsky for revising the paper and for his support, and Patricia Adduci for English correction and manuscript preparation.

Correspondence: Dra. Felisa Shokida, Callao 1769, 2ºA. C1024AAD, Ciudad Autonoma de Bs.As. Argentina. Email: felisa.shokida@gmail.com

INTRODUCTION

Identification of muscle fibers and tendons in reoperated muscles, or slipped muscles can be difficult, if tissues are not clearly differentiated and distinguished.

Vital dyes are a great aid for that purpose. They can be intravital, applied to living organisms; or supravital, applied to living cells or tissues freshly removed from the body. Intravital stains are used in different types of ophthalmic surgeries—cataract, corneal and retinal—for visualization of the internal limiting and basal membrane. (1)

Vital dyes are classified according to their chemical composition. There are xanthene dyes (fluorescein sodium), cyanine dyes (indocyanine green and infracyanine green), steroid dyes (triamcinolone acetonide acetate and flucinolone acetonide acetate), natural stains (alizarin red), arylmethane dyes (brilliant or acid blue, gentian violet, bromophenol blue and patent blue), thiazine dyes (methylene blue), and azo dyes (trypan blue and Janus green).

Azo dyes contain nitrogen in the azo form—N₅N—in their molecular structures. Sixty percent of all synthetic dyes are azo types. Trypan Blue (TB) is an azo dye, which gives bright, high intensity color, without toxicity, and its biggest advantage is cost-effectiveness. It is used at different concentrations: for cataract capsulorrhexis and pediatric cataract 0.1% and mixed with hyaluronate at 4%-; for keratoplasty 0.02%-, and for chromovitrectomy 0.06% to 0.2%. (2-4)

As TB has already been used for superior oblique tendon identification, we decided to study the use of this dye in extraocular muscular surgery, where tissues were hard to identify. (5)

The aims of this study are to evaluate the use of TB in strabismus surgery as an enhancer of tissue identification, to find the lowest optimal concentration of TB to identify specific tissues in strabismus surgery, to determine which tissues are dyed by TB, and to describe histological findings.

PATIENTS AND METHODS

All studies were performed with the informed oral consent of the subjects, conformed with the Declaration of Helsinki.

Inclusion criteria were patients with strabismus, who needed reoperation or were suspected to have muscle anomalies. Fifteen patients underwent strabismus surgery using Trypan Blue stain for tissue identification. All surgeries were performed by the same surgeon (FS). **(See Table, on page 226.)**

TB was diluted with balanced salt solution (BSS®) and tested at progressive different concentrations—100% of the product (TB 0.1%), 50%, 25%, and 12.5%. Iconographies at different dilutions were made, intraoperatively before and after the use of TB.

Tissues were stained with a cotton swab, soaked in TB, after dissecting the conjunctiva and the Tenon capsule. The use of a cotton swab to apply the dye avoids the spreading of the stain, which gives greater control when dying the area of interest. Balanced salt solution was irrigated to clean up the area. This procedure was repeated with decreasing concentrations of TB. The optimal staining was at 100% concentration (TB 0.1%).

We observed that TB 0.1% stained the muscular sheath, muscular tendon and fibrotic tissues, but it did not stain the sclera and muscle fibers. This enhanced tissue identification. In cases of strong scar tissues,

the staining process was repeated during the dissection process. This allowed progressive identification of the muscle sheath, simplifying the surgery.

Specimens obtained from the excision of tissues during surgery were processed by light microscopy. Sections from unfixed tissue were obtained with a cryostat, mounted in gelatin and examined unstained. Samples from muscle, tendons and fibrous scar tissue were fixed in 4% formaldehyde, embedded in paraffin and stained with hematoxylin and eosin, periodic acid Schiff (PAS), and Masson trichrome stain.

Out of fifteen patients we chose the first three cases to demonstrate in illustrations the stained area as follows:

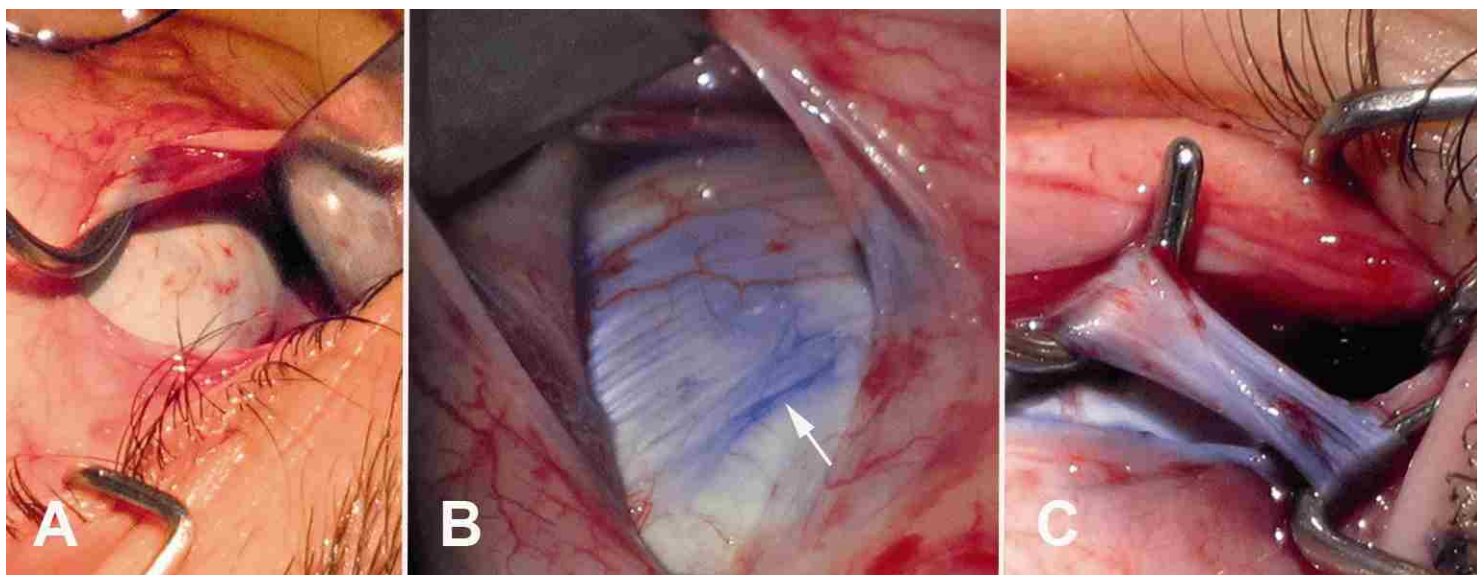
Case 1

Patient with Apert syndrome suspected to have extra ocular muscle anomalies. TB was used to identify the superior oblique muscles. TB stained the left superior oblique fibers, and made it easy to hook the muscle. (See **Figure 1 A,B,C, below**)

Case 2

Patient with previous strabismus surgery suspected to have lost muscle. The tissues that were believed to be muscle were engaged by an eye muscle hook, isolated, and TB was applied dyeing the eye muscle tendon and the muscle sheath. We saw that the lateral rectus fibers were slipped, but not lost. (See **Figure 2 A,B,C, top, next page**)

Figure 1 A (Shokida et al): Apert syndrome with agenesis of the superior oblique muscle. Absence of staining. **B and C.** Normal dyeing of the superior oblique tendon.



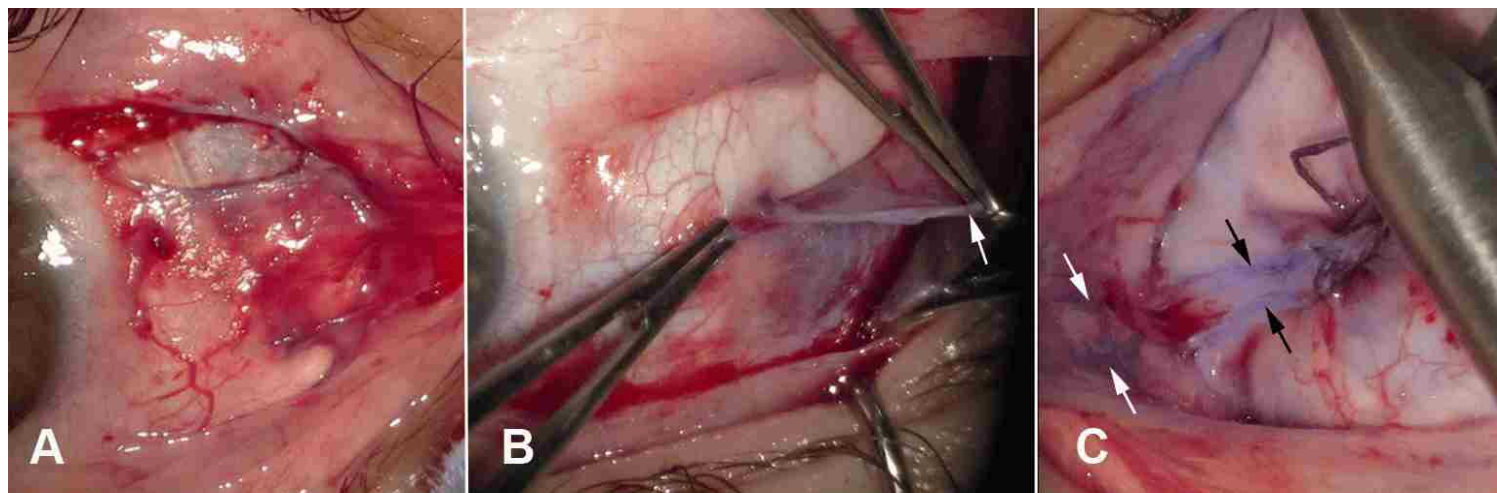


Figure 2 A and B (Shokida et al): *A: Staining of muscle sheath and intermuscular membrane (white arrow, in B) in a case of a "slipped" extraocular muscle. C. Staining of fibrotic tissues between the Tenon's capsule (between white arrows) and muscle sheath (black arrows) in repair by advancement of the remaining muscle fibers and its sheath.*

Patient with three previous surgeries showed restricted strabismus. TB was applied for identification of fibrotic tissues. (See **Figure 3 A,B,C, below.**)

Case 3

Figure 3 A (Shokida et al): *Trypan blue staining of muscle sheath and fibrotic tissues of a previously operated muscle. B. Fibrotic scars (black arrows) dyed with trypan blue. C. Stained muscle sheath (white arrow) and muscle fibers (black arrow) which are not stained with trypan blue.*

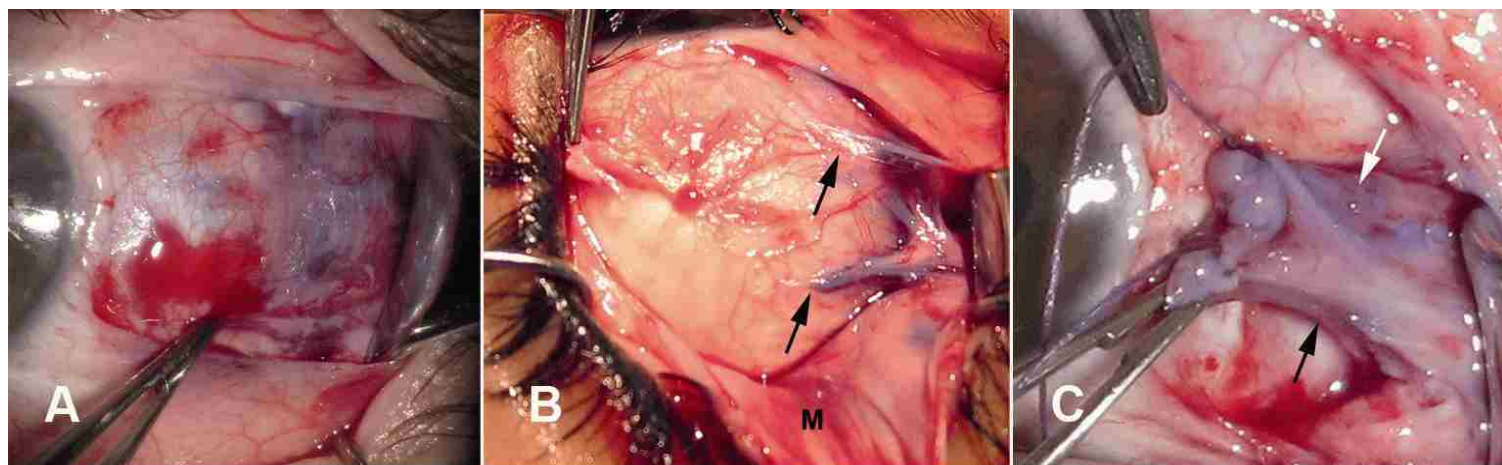


TABLE Eye Muscle Surgery Patients (15) studied with trypan blue dye

case	Strabismus type	Findings
1	Apert syndrome. First surgery.	Superior oblique muscle agenesis.
2	Lost muscle suspected. Two previous surgeries.	Slipped muscle by identification of the muscular sheath.
3	Restrictive strabismus. Three previous.	TB enhanced identification of tissues.
4	A pattern reoperation.	Superior oblique muscle tenectomy with TB stain.
5	Esotropia. Two previous surgeries.	DVD. One previous surgery. Adherence between recessed superior rectus and superior oblique muscle. AO SR recessed Scars AO re recessed medial rectus.
6	Consecutive exotropia. One previous surgery.	Fibrotic tissues in medial rectus.
7	Duane syndrome. First surgery.	Medial rectus anomalies with two fibrotic feet in the Eso Duane eye.
8	Hypocorrected exotropia. One previous surgery.	Short and fibrotic lateral rectus scars.
9	III nerve palsy reoperation.	Fibrotic tissues restrictive muscles.
10	Consecutive exotropia A pattern. Two previous surgeries.	Reoperated superior oblique muscle was difficult to identify.
11	Consecutive exotropia. Two previous surgeries.	Slipped medial rectus.
12	Exotropia reoperation.	Scars in the medial rectus muscle.
13	Esotropia. 3 previous surgeries.	Adherences and fibrotic tissues.
14	Esotropia. One previous surgery. Hypocorrection.	Adherences and fibrotic tissues.
15	Exotropia. One previous surgery. Hypocorrection.	Adherences and fibrotic tissues.

RESULTS

We found that TB 0.1% is the optimal concentration to stain the tissues of and around the extraocular muscles. Muscle sheath, tendon and fibrotic tissues are easily identified with TB. It does not stain the sclera and muscle fibers, per se.

The dye did not persist longer than 24 hours after surgery. No adverse reactions, such as post surgery inflammation or persistent staining, were seen in the 10 patients studied.

Histological findings show that frozen sections failed to disclose the TB stain in excised tissues. Light microscopy examination of fixed tissues showed a delicate thin basement like membrane surrounding the superior oblique muscle tendons. This structure was disclosed with PAS stain suggesting the presence of glycosaminoglycans.

DISCUSSION

In spite of directions and traditions, and conventions to the contrary, the authors will start the Discussion by reviewing once again, and even yet more **broadly** than in the Introduction, even yet more about the **background** of this clinical situation... before proceeding to a proper Discussion of the very Results and the rendering of our conclusions and recommended applications regarding the scientific medical experience being reported here:

In 1967, Norn described the vital staining of the conjunctiva using TB 1% by watching the stain grains in the histiocytes situated round the vessels. He found a diffuse stain in dead or degenerate cells and phagocytosis. (6)

Vital dyes are widely used in cataract surgery to stain the anterior capsule. Use of TB in cataract surgery makes the capsulorrhexis simple and safe. (7) It is also effective in

managing white cataracts. (8, 9)

Indocyanine green 0.5% (ICG) and TB 0.1% were used to stain the posterior capsule to enhance visualization during posterior continuous curvilinear capsulorrhexis. Both dyes successfully stained the posterior capsule. (10)

Healey and Crowston (11) used TB to stain antiproliferative agents in in vitro experiments.

Antimetabolites, such as mitomycin C and 5-fluorouracil, are used during trabeculectomy to inhibit postoperative scarring. (11) Franks also agrees that visualization of the antimetabolite can be facilitated using TB. (12)

Dyes are also used for vitreoretinal surgery to improve the visibility of preretinal membranes. (13) It has been shown that proliferative membranes contain fibrous structures that can be stained using TB. The inner limiting membrane can be stained using indocyanine green or infracyanine green. Ting et al treated epiretinal membrane using double staining with indocyanine green and TB. (14) Stalmans used double vital staining with TB and infracyanine green to remove the epiretinal pucker. Infracyanine green is less likely to induce toxic effects on the retinal cells than indocyanine green. (15)

TB mixed with isovolumetrically glucose 10% was also used for macular hole. (16)

Wylegała used TB at 0.02% for deep lamellar keratoplasty, (17) while Sharma used it at 0.06% to identify the complication of perforated Descemet membrane during deep lamellar keratoplasty. John found no side effect after two years follow up of endothelial keratoplasty using TB as the stain. (18) TB was used for endothelial evaluation in the cornea bank for identifying devitalized cells. (19)

Another use of this stain is for resection of conjunctival cysts. Kobayashi used a mixture of TB and sodium hyaluronate to enhance the visualization of the capsule. (20)

What is more, TB is useful for identifying extraocular muscle anomalies. They are frequent in craniofacial dysostosis, such as Apert syndrome. Cuttane reported agenesis of the superior rectus muscle. (21) Greenberg published the absence of multiple extraocular muscles in a patient with Pfeiffer syndrome. (22)

Absence and hypoplasia of the lateral rectus muscle were found in a child with congenital esotropia and mental and physical retardation, associated with duplication of the chromosome segment 7q32----q34. C. (23)

On the other hand, dyes have been questioned on their toxicity levels. Evaluation of ocular toxicity of TB in rabbit eyes showed that there were no signs of toxicity in the vitreous cavity at a concentration of 0.06%, but at 0.2% there was damage of the photoreceptors. (26)

Heilweil found no significant reduction of ERG responses, nor histological effects in the retina exposed to intravitreal TB at 0.06% in rabbits. However, it showed a disorganization of the retinal cells and there was ERG deficit at a higher concentration as 0.15%. (9)

Human corneal cells were used in in vitro experiments to quantify the toxicity of TB at different concentrations and exposure time. It was toxic to corneal endothelium and corneal fibroblasts at 0.1% concentration and exposure times more than 30 minutes. (27)

DISCUSSION of RESULTS

Although muscle anomalies can be identified with orbital MRI, TB is a useful aid

for strabismus surgery. As we presented in Case 1, the patient with Apert syndrome had superior oblique unilateral agenesis, which was easily identified using the stain.

In Case 2, TB was useful for identifying a "slipped" muscle, in a case where we believed and feared that there was a "lost" extraocular muscle. The clinical features of a "slipped" muscle may resemble a "lost" muscle. (24)

There are many diagnostic maneuvers in identifying and finding a "lost" muscle, such as saccadic velocity, forced ductions, active force generation, orbital MRI, and the oculocardiac reflex. However, Lenart and Lambert said that "no single diagnostic test provides absolute reliability for determining [*i.e., finding*] a lost muscle." (25) We found that the use of TB was a useful tool for recognizing the muscular capsule in "slipped" muscle cases.

CONCLUSIONS

As in our studies we did not find any adverse reactions, we conclude that Trypan Blue 0.1% is the optimal concentration to contrast the different tissues in strabismus surgery, because it dyes the muscle sheath, tendons and fibrotic tissues, but it does not stain the sclera and muscle fibers. It is a useful tool for reoperation in strabismus surgery.

REFERENCES

1. Rodrigues EB, Costa EF, Penha FM, et al: The use of vital dyes in ocular surgery. *Surv Ophthalmol* 2009;54(5):576-617.
2. Farah ME, Maia M, Rodrigues EB: Dyes in ocular surgery: principles for use in chromovitrectomy. *Am J Ophthalmol* 2009;148(3):332-340.
3. Brazitikos PD, Katsimpris JM, Tsironi E, Androudi S: Retinal nerve fiber layer thickness evaluation after trypan blue-assisted macular surgery. *Retina* 2010;30(4):640- 647.

4. Li KK, Tang EW, Li PS, Wong D: Double peel using triamcinolone acetonide and trypan blue in the management of myopic macular hole with retinal detachment: a case- control study. *Clin Experiment Ophthalmol* 2010;38(7):664-668.
5. Saxena R, Sinha A, Sethi H, Menon V: Trypan blue-assisted posterior tenectomy of the superior oblique. *J Pediatr Ophthalmol Strabismus* 2007;44(1):45-46.
6. Norn MS: Trypan blue. Vital staining of cornea and conjunctiva. *Acta Ophthalmol (Copenh)* 1967;45(3):380-389.
7. Venkatesh R, Veena K, Ravindran RD: Capsulotomy and hydroprocedures for nucleus prolapse in manual small incision cataract surgery. *Indian J. Ophthalmol* 2009;57(1):15-18.
8. Nakano A, Nagamoto T, Hama Y, Fujiwara T, Miyata K, Samejima T: Results of surgery on white cataract using trypan blue capsule staining to visualize capsulorrhexis. *Nihon Ganka Gakkai Zasshi* 2004;108(5):283-290.
9. Heilweil G, Komarowska I, Zemel E, Loewenstein A, Perlman I: Normal physiological and pathophysiological effects of trypan blue on the retinas of albino rabbits. *Invest Ophthalmol Vis Sci* 2010;51(8):4187-4194.
10. Pandey SK, Werner L, Escobar-Gomez M, et al: Dye-enhanced cataract surgery. Part 1: anterior capsule staining for capsulorrhexis in advanced/white cataract. *J Cataract Refract Surg* 2000;26(7):1052-1059.
11. Healey PR, Crowston JG: Trypan blue identifies antimetabolite treatment area in trabeculectomy. *Br J Ophthalmol* 2005;89(9):1152-1156.
12. Franks W: Trypan blue staining of antiproliferative agents for trabeculectomy surgery and bleb needling. *Br J Ophthalmol* 2005;89(11):1394-1395.
13. Abdelkader EA, McBain VA, Anand M, Scott NW, Siddiqui MA, Lois N: In Vivo Safety of Trypan Blue Use in Vitreoretinal Surgery. *Retina* 2010 Dec 21.
14. Ting FS, Kwok AK: Treatment of epiretinal membrane: an update. *Hong Kong Med J* 2005;11(6):496-502.
15. Stalmans P, Feron EJ, Parys-Van Ginderdeuren R, Van Lommel A, Melles GR, Veckeneer M: Double vital staining using trypan blue and infracyanine green in macular pucker surgery. *Br J Ophthalmol* 2003;87(6):713-716.
16. Lesnik Oberstein SY, de Smet MD: Use of heavy Trypan blue in macular hole surgery. *Eye (Lond)* 2010;24(7):1177-1181.
17. Wylegala E, Tarnawska D, Dobrowolski D: Deep lamellar keratoplasty for various corneal lesions. *Eur J Ophthalmol* 2004;14(6):467-472.
18. John T, Shah AA: Use of trypan blue stain in endothelial keratoplasty. *Ann Ophthalmol (Skokie)* 2009;41(1):10-15.
19. Schroeter J, Rieck P: Endothelial evaluation in the cornea bank. *Dev Ophthalmol* 2009;43:47-62.
20. Kobayashi A, Sugiyama K: Successful removal of a large conjunctival cyst using colored 2.3% sodium hyaluronate. *Ophthalmic Surg Lasers Imaging* 2007;38(1):81-83.
21. Cuttone JM, Brazis PT, Miller MT, Folk ER: Absence of the superior rectus muscle in Apert's syndrome. *J Pediatr Ophthalmol Strabismus* 1979;16(6):349-354.
22. Greenberg MF, Pollard ZF: Absence of multiple extraocular muscles in craniosynostosis. *J AAPOS* 1998;2(5):307-309.
23. Keith CG, Webb GC, Rogers JG: Absence of a lateral rectus muscle associated with duplication of the chromosome segment 7q32---q34. *J Med Genet* 1988;25(2):122-125.
24. Murray AD: Slipped and lost muscles and other tales of the unexpected. Philip Knapp Lecture. *J AAPOS* 1998;2(3):133-143.
25. Lenart TD, Lambert SR: Slipped and lost extraocular muscles. *Ophthalmol Clin North Am* 2001;14(3):433-442.
26. Veckeneer M, van Overdam K, Monzer J, Kobuch K, van Marle W, Spekrijse H: Ocular toxicity study of trypan blue injected into the vitreous cavity of rabbit eyes. *Graefes Arch Clin Exp Ophthalmol* 2001;239(9):698-704.
27. van Dooren BT, Beekhuis WH, Pels E: Biocompatibility of trypan blue with human corneal cells. *Arch Ophthalmol* 2004;122(5):736-742.

Original Scientific Article

Periosteal Flap Fixation of the Globe for Surgical Treatment of Severe Restrictive Strabismus: A Report of Eight Cases with Outcomes

REHAN AHMED, M.D., DAVID K. COATS, M.D. and
MICHAEL T. YEN, M.D.

from the Departments of Ophthalmology, Cullen Eye Institute, (all authors), Baylor College of Medicine, and Texas Children's Hospital (Dr. Coats), Houston, Texas.

ABSTRACT: **Purpose:** Severe paretic and restrictive strabismus presents a challenging surgical problem. Despite aggressive—and often multiple—surgical attempts, patients can have recurrence of large angle binocular misalignments. In this paper, we present a series of patients who underwent apically-based orbital bone periosteal flap fixation of the globe in cases of restrictive strabismus due to isolated third-nerve and sixth-nerve palsies, multiple cranial nerve palsies, and severe ocular fibrosis syndrome.

Methods: We performed a retrospective study at our institution of patients who underwent a periosteal flap fixation. In all cases presented, the creation of the periosteal flap was performed by an orbital surgeon, and the strabismus surgery and follow-up data points were performed and collected by a strabologist.

Results: A total of 8 patients underwent a periosteal flap fixation of the globe. The mean age was 48 years old. Three patients had a third cranial nerve palsy, one patient had congenital fibrosis, one patient had sixth cranial nerve palsy, and three patients had multiple cranial nerve palsies. Five patients had a medial periosteal flap constructed, and 3 patients had a temporal periosteal flap. Seven of the 8 patients had stable postoperative strabometry (binocular misalignment) measurements. A single patient required an additional procedure secondary to postoperative drift (a mild recurrence of binocular misalignment).

Conclusions: The surgical correction of severe paretic and restrictive strabismus is complex and can present a formidable challenge. The use of an orbital bone-based periosteal fixation flap, at our institution, has shown satisfactory outcomes not only with regard to improved postoperative deviation, but also, in that most patients required only this single procedure, usually after several prior unsuccessful interventions by standard strabismus surgery procedures.

Received for consideration April 27, 2011; accepted for publication June 3, 2011

Supported in part by an unrestricted departmental educational grant from Research to Prevent Blindness, Inc. (New York, NY)

Correspondence to: Michael T. Yen, MD, Cullen Eye Institute, 6565 Fannin MC-205, Houston, TX 77030, Fax: 713-798-8739, email: myen@bcm.edu

INTRODUCTION

Severe paretic and restrictive strabismus is often difficult to manage. Despite aggressive surgical attempts at correction with large resection and recession of the extraocular muscles, patients often develop recurrence of large angle binocular misalignments and compensatory anomalous head positioning. To provide a more stable post-operative binocular alignment, patients may require accessory globe fixation to achieve the goal of placing the restricted deviated eye more permanently in its primary position (1). Although there have been several innovative surgical methods described, there has been no single agreed upon surgical modality, to date, to restore the eye to its normal primary position and to maintain that position over time (2). A technique that has been used at our institution with some success is orbital bone apically-based periosteal flaps (1).

The purpose of this paper is to present a series of patients who underwent periosteal flap fixation of the globe for persistent restrictive strabismus in cases of isolated third-nerve and sixth-nerve palsy, with residual deviation after prior surgery, multiple cranial nerve palsies, and severe ocular fibrosis syndrome.

REPORT OF SELECTED CASES

We performed a retrospective study of patients who underwent such periosteal flap globe fixation for complex restrictive strabismus. In all cases presented, the surgery was performed jointly by an orbital surgeon ((MTY), and a strabismus surgeon (DKC). Surgery follow-up strabometry data points were performed and collected by a strabologist (DKC). (*See Table*)

Arbitrarily Selected Exemplary Cases:

Cranial Nerve III Palsy

Case 3

A 39 year old female presented with an exotropia (XT) and a complete adduction deficit in the left eye that had been present since childhood. She had undergone several strabismus surgeries prior to our consultation, which included a left medial rectus muscle resection of 9 mm done 16 years prior, followed by a left lateral rectus muscle recession of from "15 to 20 mm" two years later.

On examination, she had an XT of 30 prism diopters (PD) and a right face (head) turn of 30 degrees.

She subsequently underwent an apically-based medial periosteal flap fixation procedure of the left eye. At followup at 4 months after surgery, she had an XT of 20 PD with 5 degree right face turn for distance, approximately 15 degree right face turn for near. She was seen approximately 3 years later with stable measurements with an XT of 18 PD and a left hypertropia of 5 PD at distance and near, with a 15 degree right face turn. Despite only a relatively modest improvement in her primary position binocular alignment, her head posture had improved significantly and no further treatment was desired by the patient.

Congenital fibrosis syndrome

Case 4

A 2 year old male with congenital fibrosis syndrome, Marcus Gunn jaw winking, and blepharoptosis presented with a chin up position (abnormal head posture) of 10-15 degrees and an XT of 30 PD. He had undergone multiple previous eye muscle

surgeries prior to our consultation, including bilateral superior oblique tenotomies with bilateral levator aponeurosis resections, bilateral double marginal myomectomies (operated muscles unclear), and bilateral inferior rectus recession procedures. He underwent a medial periosteal flap procedure in his left eye to improve horizontal binocular alignment in the primary position. At the 6 week followup visit, he was noted to have an XT of 8 PD, with a 10 degree chin up posture. The chin up posture was minimized with 10 base up in his spectacles bilaterally.

Bilateral 6th Nerve Palsy

Case 5

A 64 year old male presented with a bilateral 6th nerve palsy caused by a pontine hemorrhage 5 years prior to our evaluation. He was status post Botox® injections to the right medial rectus muscle in the acute phase, which were unhelpful. He believed he was extremely disabled by his ocular misalignment, feeling that he was always looking at his nose with his ET of 40 PD. He underwent strabismus surgery consisting of a transposition of the vertical rectus muscles to the insertion of the lateral rectus muscle with posterior fixation suture augmentation in both eyes. After this procedure, his alignment was improved but he continued to have an esotropia of 35 PD. He underwent a bilateral temporal apically-based periosteal flap procedure, under retrobulbar anesthesia, in a staged manner. Postoperatively, he achieved single vision with a 14 base out Fresnel prism before the left eye.

Multiple Cranial Nerve Palsy

Case 6

A 45 year old woman with a right sided cavernous sinus meningioma that was treated with resection and radiation, developed a total third and fourth nerve palsy with an XT > 60 PD. She underwent a right medial periosteal flap global fixation with a simultaneous blepharoptosis repair that resulted in a postoperative deviation of 15 PD XT at month 1, but that later increased to 25 PD at 3 months postoperatively. She subsequently underwent a recession of the right lateral rectus with transposition to the lateral periosteum and a superior rectus anterior transposition to the medial rectus insertion. Following this procedure, she had an XT of 20 PD at postoperative month two. She achieved single vision with a small left face turn and she desired no further treatment. She remained stable at one year following surgery.

(Continued on page 234)

TABLE: Patient Data and Results of Surgery
(Periosteal Flap Fixation of the Globe)

Case #	Age at Surgery/	Diagnosis	Type Of Flap	Deviation PD)		Followup (Months)
	Gender			Preop'	Postop'	
1	52/F	CNP 3 (Inferior Div)	Medial	XT >90	XT 20	3
2	67/F	CNP 3	Medial	XT 50	XT 15	5
3	39/F	CNP 3	Temporal	XT 30 LHT 7	XT 20 LHT 5	4
4	2/M	Congenital Fibrosis	Medial	XT 30	XT 8	1
5	65/M	CNP 6 Bilateral	Bilateral Temporal (R then L)	ET 40	ET 10	2
6	45/F	CNP 3 & 4	Medial	XT > 60	XT 25	3
7	61/M	CNP 3,4,5 and 6	Medial	ET 40	Ortho	3
8	51/F	CNP 3,4,6	Temporal	ET 40 RHT 10	ET 8	1 wk

CNP = Cranial Nerve Palsy

DISCUSSION

In spite of Directions and traditions, and conventions to the contrary, the authors start the Discussion by reviewing once again, and even yet more **broadly** than in the Introduction, even yet more about the **background** of this clinical situation... before proceeding to a proper Discussion of the Results and the rendering of their conclusions and recommended applications regarding the scientific medical experience being reported here:

Standard strabismus surgery for extraocular muscle palsy(ies) is generally, but not always, successful for treatment of sixth nerve palsies. Treatment of third nerve palsies, however, standard surgery on the extraocular muscles often proves unsatisfactory. In cases such as these, passive globe fixation of the deviated eye to a straight ahead undeviated primary position has been shown to be an effective treatment option.

Various materials have been used to anchor the globe to the periosteum, including superior oblique tendon (4), silicon bands (5), fascia lata (6), and 5-0 polyester sutures (7). The creation of a periosteal flap as described by Goldberg et al (1) has several advantages: the tissue is autogenous and therefore problems associated with inflammatory reactions and resorption are eliminated; and the tissue is well vascularized as compared to free flaps harvested from other body sites.

DISCUSSION of RESULTS

While our results show an overall trend toward mild to modest undercorrection, the majority of patients

achieved sufficient improvement that additional surgical treatment was not required. Compared against the conventional approach to total third nerve palsy where multiple procedures are often required, our use of this approach to third cranial nerve palsies achieved relatively good and stable outcomes in a single procedure. We were able to obtain satisfactory outcomes in patients with up to 90 PD of preoperative deviation. Additionally, we have noted no major complications in harvesting the flap and fixing it to the globe.

In addition to isolated third cranial nerve palsies, the patients in our series with congenital fibrosis, bilateral sixth nerve palsies and multiple cranial nerve palsies, all achieved stable and acceptable improvement from surgery.

Sharma et al (2) recently described satisfactory outcomes for third cranial nerve palsies using a modified technique of anchoring the globe to medial periosteum with 5-0 double armed polyester suture. Although probably technically easier than the creation of a periosteal flap, potential disadvantages include less tensile strength compared to a periosteal flap, and the potential for erosion and extrusion.

Ultimately the surgical correction of severe paretic and restrictive strabismus is complex and can present a formidable challenge. The use of a periosteal flap at our institution has shown satisfactory outcomes not only with regard to postoperative deviation, but also in that most patients required only this single procedure, often after several prior unsuccessful surgical interventions.

REFERENCES

1. Goldberg RA, Rosenbaum AL, Tong JT. Use of apically based periosteal flaps as globe tethers in severe paretic strabismus. **Arch Ophthalmol.** Mar 2000;118(3):431-437.
 2. Sharma P, Gogoi M, Kedar S, Bhola R. Periosteal fixation in third-nerve palsy. **J AAPOS.** Aug 2006;10(4):324-327.
 3. Noorden Gv. **Surgical Therapy of Paralytic Strabismus.** 6th ed. St. Louis (MO): Mosby Inc; 2002.
 4. Villasenor Solares J, Riemann BI, Romanelli Zuazo AC, Riemann CD. Ocular fixation to nasal periosteum with a superior oblique tendon in patients with third nerve palsy. **J Pediatr Ophthalmol Strabismus.** Sep-Oct 2000;37(5):260-265.
 5. Bicas HE. A surgically implanted elastic band to restore paralyzed ocular rotations. **J Pediatr Ophthalmol Strabismus.** Jan-Feb 1991;28(1):10-13.
 6. Salazar-Leon JA, Ramirez-Ortiz MA, Salas-Vargas M. The surgical correction of paralytic strabismus using fascia lata. **J Pediatr Ophthalmol Strabismus.** Jan-Feb 1998;35(1):27-32.
 7. Srivastava KK, Sundaresh K, Vijayalakshmi P. A new surgical technique for ocular fixation in congenital third nerve palsy. **J AAPOS.** Aug 2004;8(4):371-377.
-

Case Report with Literature Review

Globe Fixation with Homologous Temporalis Fascia Transplant for Treatment of Restrictive Esotropia Strabismus: An Interventional Case Report and Review of the Literature

ABBAS BAGHERI, M.D., REZA ERFANIAN-SALIM, M.D.,
HOSSEIN SALOUR MD, AND SHAHIN YAZDANI MD,

ABSTRACT: Purpose: To report a case of fat adherence complication syndrome after pterygium surgery, sufficiently severe enough to create a recurring significant extraocular motility problem and its ultimate novel and successful management.

Method: A 75 year old man was referred with an acquired large angle esotropia after pterygium surgery. Multiple previous strabismus surgeries to relieve the esotropia had already been performed but failed. Bilateral poor vision obviated complaints of diplopia but his binocular visual field was halved and his vision overall and his motility vision was handicapped by this limited ocular motility in his right eye. We therefore utilized homologous adjacent temporalis fascia transplantation for re-fixation of his frozen esotropic globe in primary position.

Result of Surgery: Not only was the esotropia resolved but he also developed and regained some degree of abduction in this eye.

Conclusion: Homologous Temporalis fascia transplant can be used safely, for globe fixation in surgical treatment of severe restrictive strabismus.

Received for consideration July 5, 2011; accepted for publication August 24, 2011

Correspondence to: Abbas Bagheri, M.D., Ophthalmic Research Center, Labbafinejad Medical Center, Pasharan Ave. Boostan 9 St. Tehran, Iran. 16666. Fax: 98 21 22590607

Email: abbasbagheri@yahoo.com The authors thank Dr. Ramin Sahebghalam for depicting the schematics in Figure 2.

INTRODUCTION

Eye movements may be restricted due to scar tissue of previous operations or due to trauma. Fat adherence syndrome is characterized by the unintended invasion of and scar formation in extraconal orbital fat leading to adhesion of the globe and

extraocular muscles to the bone or periorbital thereby limiting eye movements (1-7). One of the common operations which can lead to fat adherence syndrome is pterygium surgery (8).

In mild forms of restrictive or paralytic strabismus conventional surgeries like recession / resection or transposition of

muscles can solve the problem, but occasionally, severe restrictive or paralytic strabismus requires globe repositioning and fixation in primary position by alloplastic or autogenous materials (9-15).

This case report describes the technique of globe fixation using homologous temporalis fascia for correction of severe restrictive strabismus secondary to fat adherence syndrome.

CASE REPORT

A 75-year-old man with a history of pterygium surgery 8 years ago at another center was referred to our hospital. Review of the operative report showed that medial extraconal fat had been exposed during initial surgery. The patient had been re-admitted to the anterior segment service and six operations were performed in an attempt to release the nasal adhesions, including an amniotic membrane graft, mucous membrane grafting and mitomycin C 0.02% application in different sessions and all had been unsuccessful. Because of severe adhesions, the cornea had been ruptured unintentionally in one of these attempts necessitating both a

corneal graft and cataract surgery.

Eventually the patient was referred to our strabismus service with progressive esotropia in his right eye and it's complete limitation (total fixation) in adduction. Visual acuity was counting fingers at 3 meters in the right eye because of eccentric viewing and high astigmatism and aphakia and 20/200 acuity in the left eye because of a moderate to severe cataract. The right eye was fixed in adduction with more than 60 prism diopters (PD) of esotropia (**Fig 1A, below**), and abduction was virtually absent in the same eye (**Fig 1B, below**). Severe symblepharon was seen in the nasal area of the right eye. Forced duction testing was severely positive but a force generation test showed normal power of the right lateral rectus muscle. The corneal graft was clear and the intraocular lens was well positioned. Bilateral poor vision obviated complaints of diplopia but his binocular visual field was halved and his vision overall and his motility vision was handicapped by this limited (literally absent) ocular motility in his right eye.

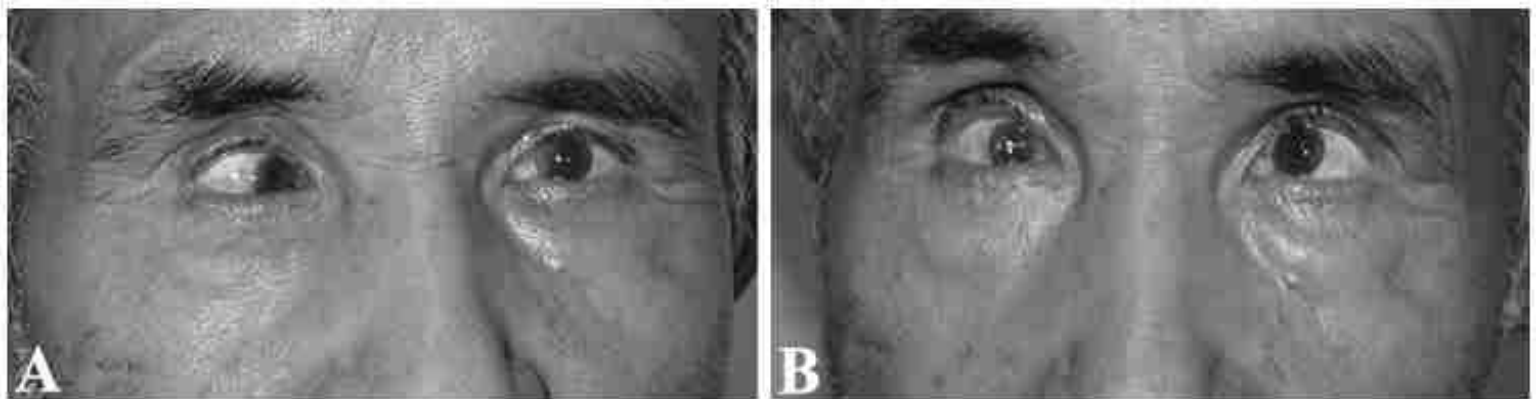

Figure 1 (Bagheri et al): Patient's appearance before his surgeries at our institution.
A: in primary position, fixing with left eye. **B:** in maximum right gaze, fixing with left eye.

We initially performed a medial rectus disinsertion, inserted a scleral traction suture in the temporal area for 3 days and covered the nasal defect with a free conjunctival graft from the other eye. However, after one month the esotropia gradually recurred so we proceeded with our globe fixation surgery.

Operative Technique

Under general anesthesia, all adhesions in the nasal area were released deep to the orbit using blunt scissors until the globe was freely moveable to the temporal side followed by temporal bulbar peritomy. Then a 2 cm vertical incision was made 3 cm temporal to the lateral canthus down to the periosteum. A free fascial strip was harvested from the right temporal muscle surface 8 cm in length and 6 mm in width, which was then cut and divided in halves into two 3mm strips except for a centimeter at their common base (end). The base of the strip was then sutured to the orbital rim periosteum temporal to the lateral canthus (**Fig 2A, right**). A Wright needle was inserted adjacent to the lateral rectus under the temporal conjunctiva deep through the orbital tissues into the extra lateral canthal incision and the two arms of the strip were drawn back to the superior and inferior corners of the lateral rectus muscle insertion (**Fig 2B and 2C, right**). The tips of the arms of the strip were sutured to the upper and lower borders of the lateral rectus muscle and the sclera with prolene 5-0 while the assistant surgeon pushed the globe outward and laterally. At the conclusion of surgery, the eye was in a 15 PD exotropic position (over-corrected) by estimation.

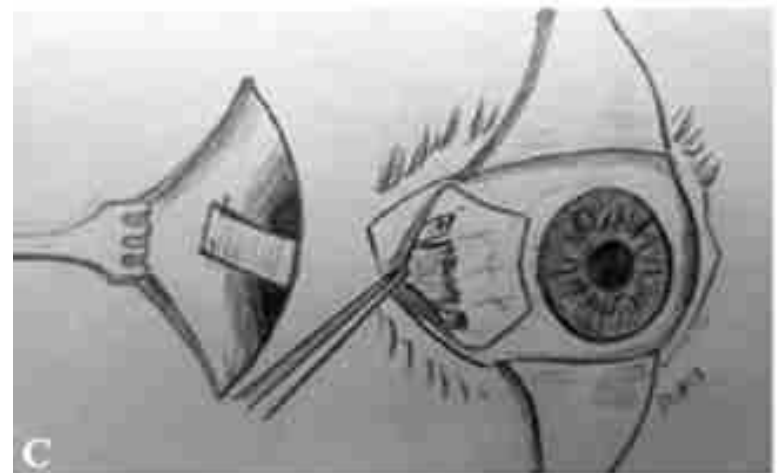
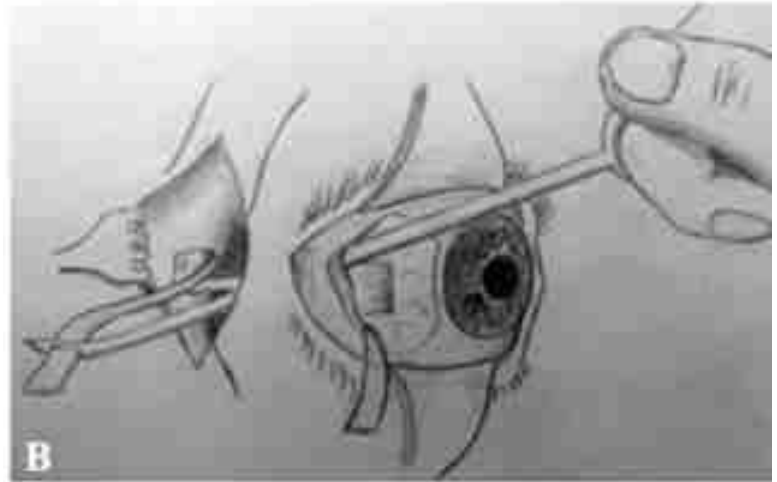
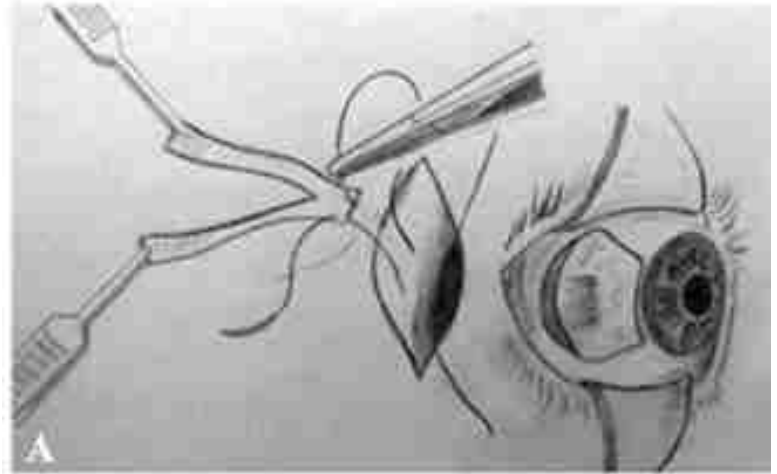


Figure 2 (Bagheri et al): Schematic presentation of the procedure. **A:** Fascial strip is being fixed over the zygomatic periosteum. **B:** Fascial strip arms are being drawn to the globe using a Wright needle. **C:** Fascial strip arms have been fixed to both corners of the lateral rectus.

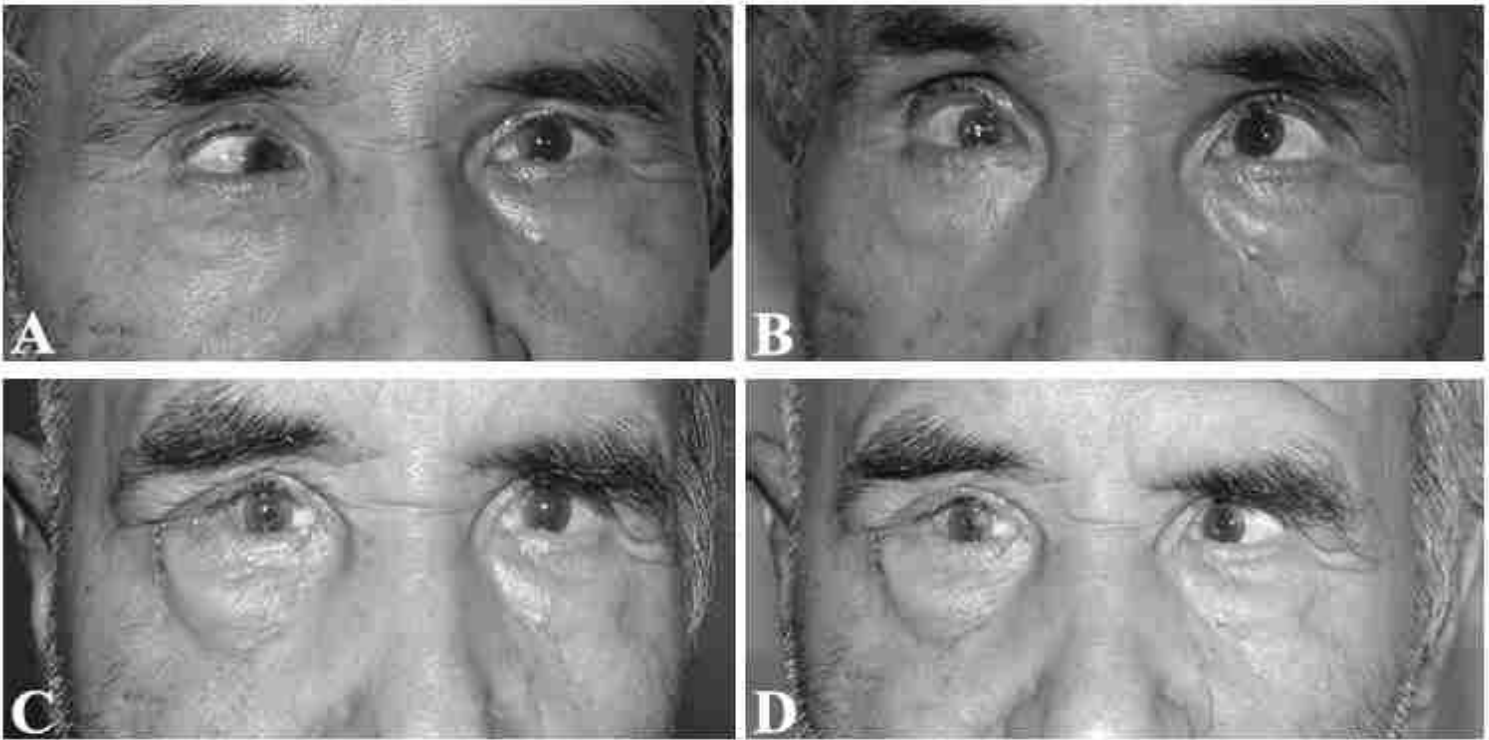

Figure 3 (Bagheri et al): Patient's appearance: TOP: before eye surgeries at our institution. **A:** primary position. **B:** right gaze. Bottom: **C:** After surgeries in primary position. **D:** After surgery in right gaze. (The Top two figures are, for comparison, repeated from two pages prior.)

Excess fascial tissues were excised and used to fill the new tissue defect in the nasal area; finally methylprednisolone (20 mg) was injected into the scarred nasal region. Betamethasone 0.1% and chloramphenicol 1% eye drops were prescribed four times daily and gentamicin ointment 1% was applied to the skin wounds twice daily for two weeks.

The day after the operation, using the Hirschberg Corneal Light Reflection Test strabometry method, the patient had 10 PD exotropia which improved to orthotropia one month later and remained stable for 2 years (**Fig 3C, above**). Unexpectedly, but to the satisfaction of all, he actually showed some abduction past the midline postoperatively.

(Fig 3D, above)

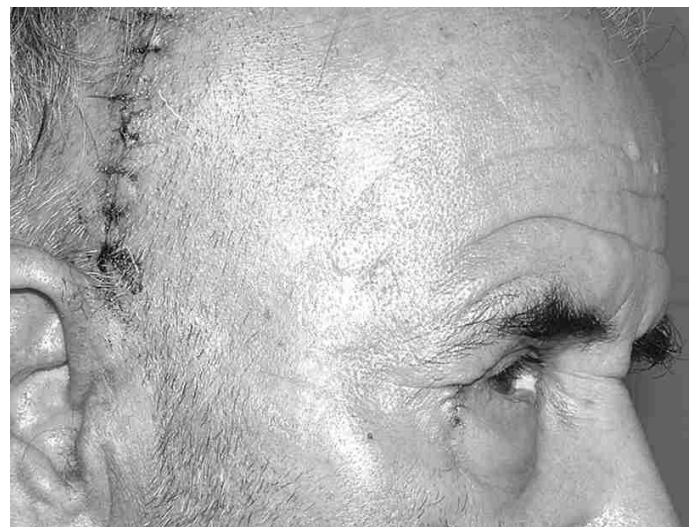

Figure 4 (Bagheri et al): Postoperative Skin scar areas in the temple and lateral canthus.

DISCUSSION

To review once again, and even yet more broadly than in the introduction, even yet more about the background of this clinical situation before discussing the results and giving our conclusions and applications regarding the experience being reported here:

Parks (1) initially described fat adherence syndrome following operation on the inferior oblique muscle. He believed the cause of this complication to be rupture of posterior tenon's capsule and violation of orbital fat leading to fibro-fatty adhesions between the globe and periorbital tissues (1). Later it was suggested that contracture in fibroconnective septae of orbital soft tissues may lead to this complication (16). Predisposing factors include poor surgical technique, bleeding into fatty tissues, trauma to soft tissue vessels, extensive cauterization and postoperative infection and inflammation (5). Fortunately, fat adherence syndrome is a rare complication following surgery or trauma in the orbit but the frequently ensuing restrictive strabismus is usually difficult to manage. In addition to release of soft tissue adhesions, synthetic materials such as supramid implants (17,18), injection of long-acting corticosteroids (17,18), and amniotic membrane transplantation (19-21) have been described for treatment of this condition.

Deep temporalis fascia is a suitable tissue for orbital and eyelid reconstructive procedures (22). It is a strong and flexible autogenous tissue which is readily available; furthermore the incision can be hidden under the hair line (Fig 4). Its thickness is less than fascia lata and it does not produce a bulge under the skin and mucosa (23). Temporalis fascia has previously been used for correction of upper lid blepharoptosis (24-26), eyelid

reconstruction (27), lateral canthus reconstruction (28) and socket reconstruction (29-30).

One type of paralytic strabismus which produces a wide range of limitations in eye movements is third nerve palsy; its similarity to fat adherence syndrome include significant limitation in eye movements while in contrary to fat adherence syndrome there is a little available power to correct ocular or binocular misalignment in third nerve palsy. This condition has been treated using a wide range of approaches from simple strabismus operations to globe fixation (31-44).

Salzar et al (45) used fascia lata for correction of strabismus in third cranial nerve palsy to fixate the globe in adduction. However, we found no report on the use of temporalis fascia in restrictive strabismus secondary to fat adherence syndrome. The use of temporalis fascia instead of fascia lata entails certain advantages. The most important drawback in the use of fascia lata is the need to perform simultaneous surgery at a different location and special positioning of the patient during surgery which adds to surgical time and morbidities (46). In addition the scar in the temporal area is nicely buried underneath the hair but the thigh scar is conspicuous.

However, it must be noted that the temporal incision for harvesting temporalis fascia incurs potential complications such as local alopecia, damage to the facial nerve, hemorrhage and infection (23).

Although long term recurrence of eye misalignments in paralytic strabismus especially third nerve palsy after using fascia lata has been reported, (17, 45) we believe that the use of temporalis fascia is a good method for correcting restrictive strabismus due to orbital fat adherence syndrome.

REFERENCES

1. Parks MM. The overacting inferior oblique muscle. **Am J Ophthalmol** 1974; 77:787-797.
2. Wright KW. The adherence syndrome and strabismus after retina surgery. **Ophthalmology** 1986; 93:411-415.
3. Brooks SE, Yu JC, Preston D, Johnson MH. Restricted ocular motility after orbital trauma-studies with an animal model. **J AAPOS** 1998; 2:246-252.
4. Kushner BJ. The inferior oblique muscle adherence syndrome. **Arch Ophthalmol** 2007; 125: 1510- 1514.
5. Dunlap EA. Surgery of muscle adhesions and effects of multiple operations. **Br J Ophthalmol** 1974; 58: 307-312.
6. Kerr NC. Fat adherence syndrome: an animal model. **J AAPOS** 2004; 8: 349- 356.
7. Lee HBH, Nunery WR. Orbital adherence syndrome secondary to titanium implant material. **Ophthal Plast Reconstr Surg** 2009; 25: 33-36.
8. Velez FG, Ela- Dalman N, Rosenbaum AL. Incomitant esotropia following pterygium excision surgery. **J AAPOS** 2006; 10: 94.
9. Goldberg RA, Rosenbaum AL, Tong JT. Use of apically based periosteal flaps as globe tethers in severe paretic strabismus. **Arch Ophthalmol** 2000; 118:421-437.
10. Awad AH, Shin GS, Rosenbaum AL, Goldberg RL. Autogenous fascia augmentation of a partially extirpated muscle with a subperiosteal medial Orbitotomy approach. **J AAPOS** 1997; 1: 138- 142.
11. Murthy R. Lateral Fixation of sclera to the periosteum with medial rectus disinsertion for severe myopic strabismus fixus. **Indian J Ophthalmol** 2008; 56: 419- 421.
12. Yu JC, Brooks SE, Preston D, Johnson MH. Treatment of posttraumatic ocular dysmotility using autogenous buccal fat grafts in a porcine model. **Plast Reconstr Surg** 1999; 104: 719- 725.
13. Brooks SE, Ribeiro GB, Archer SM, Elner VM, Del Monte MA. Fat adherence syndrome treated with intraoperative mitomycin- C: a rabbit model. **J Pediatr Ophthalmol Strabismus** 1996; 33: 21- 27.
14. Sondhi N, Ellis FD, Hamed LM, Helveston EM. Evaluation of an absorbable muscle sleeve to limit postoperative adhesions in strabismus surgery. **Ophthalmic Surg** 1987; 18: 441- 443.
15. Scott AB, Miller JM, Collins CC. Eye muscle prosthesis. **J Pediatr Ophthalmol Strabismus** 1992; 29: 216-218.
16. Parks MM. Discussion of Wright KW. The fat adherence syndrome and strabismus after retina surgery. **Ophthalmology** 1986; 93:415.
17. Helveston EM. Complication in strabismus surgery. In: surgical management of strabismus an atlas of strabismus surgery. 4th ed. St Louis: Mosby; 1993: 305-344.
18. Isenberg SJ, Apt L. Inferior oblique weakening procedure: techniques and indications. In: Rosenbaum AL, Santiago AP (eds.). Clinical strabismus management principles and surgical techniques. First ed. Philadelphia: WB. Saunders; 1999: 449-458.
19. Yamada M, Shinoda K, Hatakeyama A, Nishina S, Mashima Y. Fat adherence syndrome after retinal surgery treated with amniotic membrane transplantation. **Am J Ophthalmol** 2001; 132: 280-282.
20. Trumler AA, Boisvert C, Roa AM, Kikkawa DO, Granet DB. Restrictive strabismus following pterygium excision surgery combined with amniotic membrane transplantation: A retrospective case review. **J AAPOS** 2010; 14: 29.
21. Shimazaki J, Shinozaki N, Tsubota K. Transplantation of amniotic membrane and limbal autograft for patients with recurrent pterygium associated with symblepharon. **Br J Ophthalmol** 1998; 82: 235-240.
22. Neuhaus RW, Shorr N. Use of temporal fascia and muscle as an autograft. **Arch Ophthalmol** 1983; 101:262-264.
23. Thomas DA, Khalifa YM. Temporalis fascia in the management of gold eyelid weight extrusion. **Ophthal Plast Reconstr Surg** 2005; 21:153-155.
24. Fan J. Frontalis Suspension technique with a temporal-fasciae-complex sheet for repairing blepharoptosis. **Aesth Plast Surg** 2001; 25:147-

- 151.
25. Baker RH, de Silva JD, Henderson HWA, Kirkpatrick N, Joshi N. A novel technique of harvesting temporalis fascia autograft for correction of recurrent blepharoptosis. **Ophthalmic Plast Reconstr Surg** 2005; 21:298-300.
26. Kokot W, Poljanowski P. Suspending of blepharoptosis on temporalis fascia sling: our own experience. **Klin Oczna** 1998; 100:393-395.
27. Holt JE, Holt GR, Krik MV. Use of temporalis fascia in eyelid reconstruction. **Arch Otolaryngol** 1985; 111:165-167.
28. Copcu E, Sivrioglu N, Koc B, Er S. Reconstruction of the lateral canthus with trilobed skin flap and temporalis fascia graft. **Plast Reconstr Surg** 2006; 117:2514-2516.
29. Foster JA, Castro E, Papay FA. Reconstruction of the irradiated contracted socket with an expanded superficial temporalis fascial flap. **Am J Ophthalmol** 1999; 127:621-622.
30. EL- Khatib HA. Prefabricated temporalis fascia pedicled flap for previously skin-grafted contracted eye socket. **Plast Reconstr Surg** 2000; 106:571-575.
31. Saunders RA, Rogers GL. Superior oblique transposition for third nerve palsy. **Ophthalmology** 1982; 89 : 310-316.
32. Solares JV, Riemann BI, Zuazo ACR, Riemann CD. Ocular fixation to nasal periosteum with a superior oblique tendon in patients with third nerve palsy. **J Pediatr Ophthalmol Strabismus** 2000; 37: 260-265.
33. Sato M, Maeda M, Ohmura T, Miyazaki Y. Myectomy of lateral rectus muscle for third nerve palsy. **Jpn J Ophthalmol** 2000; 44: 555-8.
34. Morad Y, Kowal L, Scott AB. Lateral rectus muscle disinsertion and reattachment to the lateral orbital wall. **Br J Ophthalmol** 2005; 89: 983-985.
35. Velez FG, Thacker N, Britt MT, Alcorn D, Foster RS, Rosenbaum AL. Rectus muscle orbital wall fixation: a reversible profound weakening procedure. **J AAPOS** 2004; 8: 473-480.
36. Taylor JN. Surgical management of oculomotor nerve palsy with lateral rectus transplantation to the medial side of globe. **Aust N Z J Ophthalmol** 1989; 17: 27-31.
37. Brooks SE, Olitsky SE, deB Ribeiro G. Augmented Hummelsheim procedure for paralytic strabismus. **J Pediatr Ophthalmol Strabismus** 2000; 37: 189-195.
38. Morad Y, Nemet P. Medial transposition of the lateral rectus muscle in combined third and fourth nerve palsy. **J AAPOS** 2000; 4: 246-247.
39. Yu YS, Choi DG. Medial transposition of the lateral rectus muscle in experimentally induced medial rectus paralysis. **Korean J Ophthalmol** 1991; 5: 9-14.
40. Sharma P, Gogoi M, Kedar S, Bhola R. Periosteal fixation in third nerve palsy. **J AAPOS** 2006; 10: 324-327.
41. Srivastava KK, Sundaresh K, Vijayalakshmi P. A new surgical technique for ocular fixation in congenital third nerve palsy. **J AAPOS** 2004; 8: 371-377.
42. Daniell MD, Gregson RM, Lee JP. Management of fixed divergent squint in third nerve palsy using traction sutures. **Aust N Z J Ophthalmol** 1996; 24: 261-5.
43. Ela-Dalman N, Schwarcz RM, Velez FG. Suture fixation system as globe tethers in severe paralytic strabismus. **J AAPOS** 2006; 10: 371-372.
44. Yonghong J, Kanxing Z, Wei L, Xiao W, Jinghui W, Fanghua Z. Surgical management of large-angle incomitant strabismus in patients with oculomotor nerve palsy. **J AAPOS** 2008; 12: 49-53.
45. Salazar-Leon JA, Ramirez-Ortiz MA, Salas-Vargas M. The surgical correction of paralytic strabismus using fascia lata. **J Pediatr Ophthalmol Strabismus** 1998; 35: 27-32.
46. Wheatcroft SM, Vardy SJ, Tyers AG. Complications of fascia lata harvesting for ptosis surgery. **Br J Ophthalmol** 1997; 81: 581-583.

Essay: Optically Obvious: Strabometry: CLRTs (Corneal Light Reflection Test*(s)) (i.e.: Hirschberg's and Krimsky's) are Tester (EXAMINER) MONOCULAR tests, NOT Binocular.

Virtually all human eye rendered optical measurements in our world are performed monocularly for maximum accuracy and precision. One solid and known visual line is always better drawing ray diagrams than two, right?

Isn't that totally obvious?

Why then is there no such description for the strabometry in published reports?

A common camera will provide that automatically having only one optical system. Humans have two optical systems, two eyes, and they like to use both of them all the time, because it normally provides a stereo view.

But geometrically and optically that is complicated, problematic, and open to errors, right? Monocularly, we don't need to determine ocular dominance.

Hirschberg and Krimsky said nothing about how to perform their tests regarding this aspect, and few authorities in strabology have even considered, in their recitation of these tests, the testing method.

Then we reviewed all of our strabology text library and could only find one or two articles that even considered the examiner's sighting in describing the performance of these tests, and only one who even inferred that monocular execution might even be possible, or acceptable.

This matter came to our own attention when we first embarked on the practice of

strabology some forty odd years ago, and in an effort to improve the necessary measurement of strabismus at a distance of at least 20 feet or 6 meters, as was recommended by all strabismus surgeons we listened to, we took up the use of telescopic aids, and dismembered a pair of binoculars to provide us with two monocular telescopes, upon which we mounted focal Welch-Allen hand lights, aligned through the hinge holes perfectly with the optics of the telescope, to perform CLRTs at distance for strabismus diagnosis and surgical planning. We reported the device and adopted it for regular use. (Optical Aid for Performing Hirschberg and Krimsky Test at Distance. J Pediatr Ophthalmol 1973; 10:208-209).

In the article we noted and emphasized

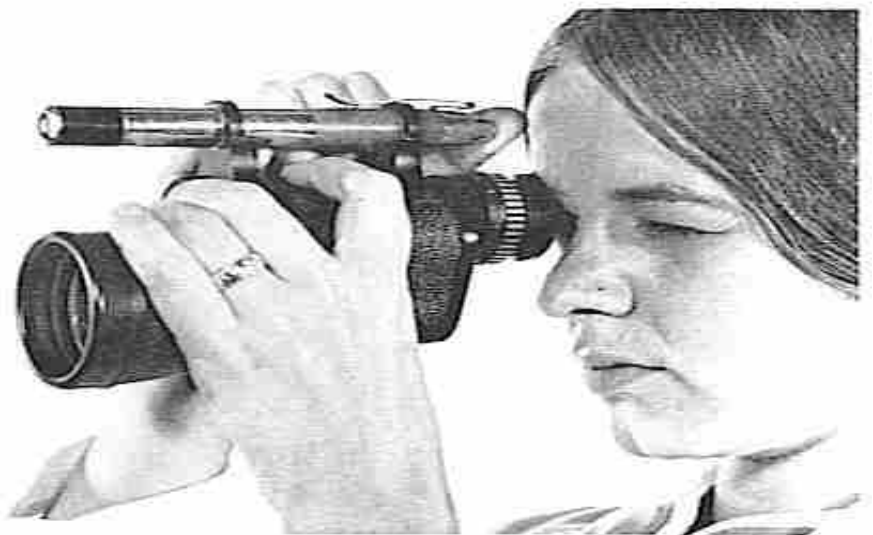

Fig. 1: Optical aid for performing corneal light reflex tests at distance.

the importance of performing these CLRTs monocularly, and that it was absolutely required and natural using this monocular device for "distance" strabometry.

Funny, but apparently, although requiring everyone in my clinics to use the monocular telescope with its perfectly (horizontally, and most important direction, of course, at least) parallel aligned light for distance horizontal strabometry measurements, I never emphasized in my teaching the importance of using this monocular CLRT technique for nearer examination distances, as I myself did all the time, without even thinking about it. I held my muscle light directly underneath my open observing eye. The perfect optical geometry was second nature to me and its precision and accuracy was assured and insured. Most of my students, I found now, do their CLRTs for nearer distances binocularly, even today...

The danger of binocular strabometry is simply that you no longer can be at all sure (i.e., much, much less than *absolutely* sure which you sure should be before cutting on someone?) of the geometry of your strabometry! Where is your binoculus?

From what point in space are you really looking at your strabismic subject?

And just where do you hold your fixation light or target relative to your eyes? And do you have a dominant eye? And which one? And how dominant?

Just where is YOUR BINOCULUS? And are you aware that any horizontal gaze you are using can shift your dominance instantly without your even knowing it toward the side of your gaze?

Take an extreme example: you are right handed so you hold your fixation light on the right, somewhere near your right eye. Say you rest your right hand and the muscle light on the side of your cheek to steady it. But it is

your left eye that is quite dominant for one of many reasons, so that is where your Binoculus really is.

Look in the mirror with a tape or ruler. How misaligned are these two points which should be 100% aligned for geometric perfection in any CLRT.?

That's 10cm on my mug. That induces an error of 30 prism diopters doing near strabometry at one third of a meter on your patient. Well, that's only maybe five or 10 mm of surgery, plus or minus, right?

REMOVE ALL these potential major errors in your strabometry.

Just shut one eye and perform CLRTs MONOCULARLY ALWAYS, (with your fixation target vertically aligned immediately below it, always.)

* footnote:

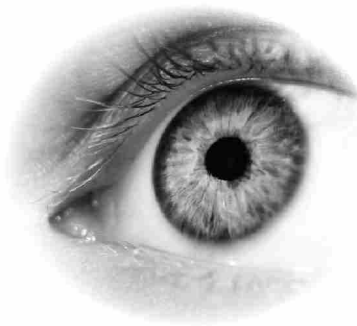We regularly term these tests "corneal light reflection tests" (a form of strabometry), to avoid the all too common error of calling this a corneal reflex test, which is not semantically wrong since our dictionaries accept "reflex" as equal to "reflection", which it really is not per se, but that invites and demands confusion with the neurologic corneal touch phenomenon of the same name. Yes, it is not wrong to call a light reflection a light reflex - except in this reference to the cornea (this situation) where it would be so easily confused with an entirely different medical entity.

The now also popular Brückner test is also performed, like these tests, but with a retinoscope or ophthalmoscope since coaxial lighting is mandatory. CLRTs can also be done that way, eliminating the unavoidable vertical error when using a muscle light below the examiner's observing eye (and any horizontal error unintended but perhaps unappreciated as well).

Prisms in the Northern Lights
**The Science of
Orthoptics**

**XIIth
International
Orthoptic Congress**

June 26 - 29 / 2012
Westin Harbour Castle



Toronto
Ontario | Canada



INTERNATIONAL
ORTHOPTIC
ASSOCIATION

www.torontoioacongress.org

Vision / Visual Acuity / Amblyopia

The Perceptual Consequences of Interocular Suppression in Amblyopia. Maehara G, Thompson B, Mansouri B, Farivar R, Hess RF. *Invest Ophthalmol Vis Sci* 2011; 52:9011-9017 [Authors Conclusions]

Amblyopes have monocular deficits in contrast perception but dichoptic deficits in luminance perception, suggesting that suppression in its mild form involves luminance processing. (Dr. Goro Maehara. Email: goro@fechner.c.u-tokyo.ac.jp)

Efficacy of a Web-Based Intervention to Improve and Sustain Knowledge and Screening for Amblyopia in Primary Care Settings. Marsh-0Tootle WL, McGwin G, Kohler CL, Kristofco RE, Datla RJ, Wall TC. *Invest Ophthalmol Vis Sci* 2011; 52: 7160-7167 [IOVS Synopsis]

Cycloplegic and Noncycloplegic Refractions of Chinese Neonatal Infants. [from IOVS Newsletter]

Chinese neonatal infants are shown, with cycloplegic retinoscopy, to be highly hyperopic even though they are at high risk to become myopic later in life. They have high amounts of tonic accommodation so that their average noncycloplegic vision is almost emmetropic. (thornf@neco.edu)

Binocular Vision and Stereopsis

Use of Monocular and Binocular Visual Cues for Postural Control in Children. Barela JA, Sanchez M, Lopes AG, Razuk M, Roraes R. *J Vision* 2011; 11(12) article 10 [Authors Conclusions]

These results suggest that development of the visual system is not fully completed until the age of 12 years and that

eye movement and binocular vision might play an important role in how visual cues are coupled to body sway. (Dr. Jose Barela. jose.barela@cruzeirodsul.edu.br)

LASIK-Induced Monovision May Significantly Reduce Stereoacuity, Contrast Sensitivity [from the AAO Academy Express]

This prospective study included 25 presbyopic patients with a spherical refractive error between 3.50 D and 6.50 D and astigmatism between 0.000 D and 4.00 D. The dominant eye was corrected for far vision; the non-dominant eye, for near with an add of +1.25 D of myopia. At three months more than 90% achieved a binocular uncorrected distance and near visual acuity of 0.0 logMAR or better. However, stereoacuity was significantly worse in all patients ($P < .001$), and the loss of visual discrimination capacity was significant in non-dominant eyes and under binocular conditions ($< .005$). Contrast sensitivity also diminished, especially in the non-dominant eye and with binocular vision. (*J Cataract Refractive Surgery*, Sept.2011)

Stereoacuity Thresholds Before and After Visual Acuity Testing. Smith SJ, Leske DA, Hatt SR, Holmes JM. *Ophthalmology* 2011, Available Online September 14. [Authors Conclusions]

Stereoacuity thresholds do not deteriorate after visual acuity testing, and therefore measurements of stereoacuity do not need to precede visual acuity measurement or other tests that involve short periods of dissociation. (Dr. Holmes, Dept Ophthalmology, Mayo Clinic, Rochester MN 55905)

The Application of 3D Representations in Face Recognition. Schwaninger A, Yang

J. Vision Research 2011; 51: 969-977.

Highlights

- This research provides evidence in support of the existence of 3 D face representations.
- Participants were required to match frontal views of faces to silhouettes of the faces.
- Profile, silhouette, and line-drawing faces were used to compare the difference.
- The face inversion effect and other race effect were demonstrated in 3D face representation. (*Jisien Yang. FAX: 41-43-336-0100, Switzerland*)

Egocentric Localization

Environmental Surfaces and the Compression of Perceived Visual Space.

Bian Z, Anderson GJ. J Vision ARVO 2011.
[Authors conclusions]

These results suggest that the perceived visual space when viewing a ground surface is less compressed than the perceived visual space when viewing a ceiling surface and that the perceived layout of a surface varies as a function of the type of the surface. (Anderson@ucr.edu)

Strabismus Pathophysiology

Predictability of Visual Function and Nerve Fiber Layer Thickness by Cross-Sectional Areas of Extraocular Muscles in Graves Ophthalmopathy. Wei YH, Chi MC, Liao SL [Authors conclusions]

For patients with Graves ophthalmopathy, the cross-sectional area of all rectus muscles was significantly correlated with visual function. The enlargement of extraocular muscles can be a sign of optic neuropathy prior to perceived clinical symptoms. Furthermore, it is possible to predict visual function change using the cross-sectional area of all rectus muscles. (*Shu Lang Liao, Dept Ophthalmology,*

National Taiwan University Hospital Chung Shan South Rd, Taipei, Taiwan)

Visual Suppression in Intermittent Exotropia During Binocular Alignment. [from IOVS Newsletter]

Children who grow up with an occasional squint keep binocular vision but learn to suppress input from one eye when it deviates. In this article, the authors show that this suppression can be triggered by a mismatch between the retinal images, simulating the effects of squint, even when the eyes are correctly aligned.

(I.s.pedraza@ncl.ac.uk)

Extraocular Muscles

Intramuscular Innervation of Primate Extraocular Muscles; Unique Compartmentalization in Horizontal Rect[US MUSCLES]. da Silva Costa RM, Kung J, Poukens V, Yoo L, Tychsen L, Demer JL. Invest Ophthalmol Vis Sci 2011; 10-6651. [Authors Conclusions]

Consistent segregation of intramuscular motor nerve arborization suggests functionally distinct superior and inferior zones within the horizontal rectus EOMs in both humans and monkeys. Reduced or absent compartmentalization in vertical rectus EOMs supports a potential functional role for differential innervation in horizontal rectus zones that could mediate previously unrecognized vertical oculorotary actions. (*Dr. Demer. jld@ucla.edu*)

Edited by P.E. Romano, MD, MSO. Abstracts are selected on the basis of interest to our readers. To avoid duplication you will find none are from **The American Orthoptic Journal**, **The British Orthoptic Journal**, **The Journal of the American Association for Pediatric Ophthalmology and Strabismus**, **The Journal of Pediatric Ophthalmology and Strabismus**, or **Strabismus**, as most of our readers already subscribe to and/or read them. Publication herein does not constitute endorsement, recommendation or a validation of author's conclusions.

HYDE PARK EDITORIAL : The Editor's Soapbox, Sandbox & B'LOG (Prehistoric) Since 1985

CONSCIOUSNESS: A Function of Stereoscopic Vision via the Egocenter... Machine Vision, Glassless Rims!=

Stereoscopic 3 Dimensional depth perception vision remains
the Acme, Epitome and GOAL of all of both (monocular) vision and
Binocular Vision.

It's the Very Foundation of
Ego-Centric Localization,
which is Your Very Own
Cornerstone of SPACE and
your respective unique world
around you we each live in 3D.




We've got some leftovers from my first editorial on pages 205-206 about egocentric localization, noted again in the subtitle above...which we pursue here.

First, we think we are right about egocentric localization, so since we put that editorial to bed, have looked a bit further about it. The egocenter has been anatomically located. It gets input from all senses, some of which have been traced to it. It may be the very site of our sense of CONSCIOUSNESS!!!! It is probably organized like a topographical map of the external world (which naturally would be 3D and based on stereoscopic visual information and experience).

DO WE NEED STILL MORE REASONS FOR THE IMPORTANCE TO LIFE OF NORMAL BINOCULAR VISION AND STEREOPSIS? WHAT MORE IS THERE?

Excuse me but I have some more very heavy reading to do!...



Second, with regard to the orthoptic professional situation...

After reading once again Kyle Arnoldi's editorial in the last issue of this publication about the future of orthoptics, there is no turning back the pages of time. So the only real solution to the enigma of the Stereo Sues that we may be or are not treating as fully, correctly or as hard and thoroughly as we should, to obtain a full normalization of binocular vision, if it is at all possible, as they mature and grow up:

IS: to do what she did: seek the help of those who are able, wherever they are. And for now it appears that since orthoptists are no longer available for one reason or another to do this, it seems that only certain members of the optometric profession can fill that need now. Primarily, we think, if only because they are independent eye professionals and unlike orthoptists do not have to do only the bidding of an ophthalmologist or strabologist whose practices and interests concentrate on surgery and who don't have the time or incentives to worry about anything more than "beautifully straight eyes" now! Many orthoptists in the past operated their own practices more or less independently, under remote supervision and would undertake an occasional "Stereo Sue" after the surgeon did his best, but are there any who do that now? We'd certainly like to know.

But for the very present, the best we think we can offer would be a directory of members of the COVD, "The College of Optometrists in Vision Development" (COVD) or directions to their website (covd.org) It is an international, non-profit optometric membership organization that provides education, evaluation and board certification programs in behavioral and developmental vision care, vision therapy and visual rehabilitation. ("VISION TRAINING", which we have officially opposed forever it seems heretofore). The organization consists of doctors of optometry, vision therapists and other vision specialists...

So we plan to enable that route for those in our profession and their patients who are interested in pursuing it. That includes also determining, approximately at best of course, the cost in time and dollars such as that expended by Stereo Sue in achieving what she did, so that sort of information can be shared by the strabologist and patient (and any insurers who should be asked to cover these expenses) in making decisions and referrals...

My somewhat radical (foregoing) recommendations on this subject are also the product of recent experiences we have had with organized orthoptics. The damage inflicted on the profession of orthoptics and the subspecialty of ocular motility are not likely to be undone in the near future. Those of us particularly interested will have to be happy with the efforts of the ISA, the ESA and similar organizations, such as Ken Wrights' somewhat annual strabismus meetings....as long as they may last in this pediatric ophthalmology marketing takeover. And I still say that PO &S is too darn much today for solitary MDs to be competent at... It was when I entered it 40 years ago and it is even more, much more substance now than it was then.....

My concerns on this were the subject also of editorials over the years, inflamed recently by our efforts to cooperate with the IOA for some mutual benefits, upon their repeated invitation, but we got so little response from the IOA membership at large. That was most disappointing. But they have changed. They are not the same profession they were. Yes, there are still some orthoptists who still are very much interested in their original profession and in binocular vision and strabismus still, but only a handful or two it seems out of what are reputed to be somewhere near ten thousand members?!!

The history of orthoptics is not easily discovered but I found a remarkably good history in Kenneth Wybar's volume. VI, 1973.....;

of Sir Steward Duke Elder's last edition of his huge textbook of ophthalmology.... It is noted there that orthoptists, as such, started in England in the 1930's (?students of? maybe C.M. Maddox?) and spread from there to the world. We noted that it is only still there, in England (and maybe former colony, Australia) that we find still serious orthoptists who have not thrown in the proverbial towel....

At the same time we sense that the M.D. side of the team is suffering similarly.

I think this is another manifestation of the overwhelming nature of the ocular motility science by the massiveness and demands of the "rest".of pediatric ophthalmology ex strabology... Being an expert in binocular vision and strabismus was per se more than a full time job all by itself, and it remains so, only more so with the increasing knowledge. So how can one in medicine double or triple the knowledge and expertise it takes to practice a branch of medicine. Surely it has doubled or tripled since Marshall Parks started his fellowship program shortly before I chose to be a strabologist in 1967, just after they started Medline, etc. I say P.O. is a mistake. Undo it.

Especially in this day and age when everyone is looking for employment that requires less of their time and effort than it traditionally took ? Especially all the women now in medicine, virtually all of whom seem to want to be full time mothers as well??? (I am leaving the care of several professionals who are smarter than older doctors, but far less willing to care for their patients and their illnesses. I seriously miss my old care-givers... I can take better care of myself alone than they do now... I always did prefer to make *my own* mistakes.)

In both cases, COs and MDs, the current economics of the medical professions has a lot to do with it... everyone now is badly in debt and just scratching out a living in the face of continued threats from the governments around the globe. And medicine is paradoxically (we seem to be using that word more and more these days...)

responsible for our own desperate situation by prolonging the lives of people, the medically horrendously expensive part of the lives of so many people. Personally, I was pretty cheap until I hit 65, but I have wracked an awful lot of bills since then starting with open heart surgery and, most recently, my three day stay for diagnosis and insertion of a pacemaker, the bill for which aimed at Medicare was \$184,000 (that is not a typo error) *one hundred and eighty four thousand dollars* for 3 days. In Tuesday AM, out Friday AM.). Add my bills for two days in Nevada where I tried to die, and a day of O.P. tests before admission back in Denver, and you have a quarter million dollar bill.

We can't afford me., neither can I

Here's a quick timely chuckle for this issue: More "SLIPPING" of muscles. finger muscles here.

CLOSE TO HOME

By John McPherson



Foolishly, Luigi had eaten a plate of barbecued spareribs on his lunch break.

OK: Off editorials and on to Blog, starting as usual with stereoscopic binocular vision. First, here's a nice spring meeting in Florida you might wish to take in:

The scientific literature shows 3D stereoscopic viewing is a great tool for enlarging our knowledge in new directions:

Once again 3D out does 2D here too. (See below)




Call for Papers

Biomedical Optics and 3-D Imaging

Miami Hilton Downtown • Miami, Florida, USA
29 April – 2 May 2012

Submit Your Paper Now!

Submission Deadline: 14 December 2011
Pre-Registration Deadline: 19 March 2012

Visit: www.osa.org/biomedicaloptics for more information

Photo credit: Diaspro, Alberto; et al. Multi-Photon excitation microscopy. Biomedical Engineering Online, 2006, 5:36.

42 PHOTONICS MEDIA

BioPhotonics • November/December 2011

JOURNAL OF VISION
www.journalofvision.org

doi: 10.1167/11.13.27
Journal of Vision November 30, 2011 vol. 11 no. 13 article 27

Three-dimensional information in face recognition: An eye-tracking study

Olga Chelnokova¹ and
Bruno Laeng²

 Author Affiliations

Abstract

One unresolved question about face perception is: what is the role of three-dimensional information in face recognition? In this study, recognition performance was compared across changes in viewpoint in different depth conditions: a 2D condition without stereo information and a 3D condition where stereo information was present (by viewing the same face images as anaglyphs through 3D glasses). Subjects' eye movements were recorded during both 3D and 2D sessions. The findings revealed that participants were more accurate in the 3D condition. Moreover, individual differences in interpupillary distance predicted recognition performance in the 3D but not in the 2D condition. A "region of interest" analysis of gaze data showed that rich volumetric properties provided by certain facial features (e.g., the nose and the cheeks) were attended more in the 3D condition compared to the 2D condition. Taken together, these findings support the conclusion that face recognition across viewpoint transformation is facilitated by the addition of stereoscopic depth cues.

Keywords

face recognition eye movements depth perception stereo vision
anaglyphs 3D interpupillary distance

3-D TV appears not to raise seizure risk in children with epilepsy.

AMA 5 dec 2011
HealthDay (12/5, Mozes) reports, "Children with epilepsy do not appear to face an increased risk for seizures while watching 3-D TV," according to a study presented at the American Epilepsy Society's annual meeting. The study of "100 children (average age 12) who had epilepsy or were deemed to be at risk for epilepsy" revealed, however, that "about one in five of these children is vulnerable to other unpleasant reactions when viewing 3-D television, including nausea, headaches and dizziness." The study authors "suggested that seizure risk is probably more a function of differences in TV content rather than TV technology, with certain patterns, colors and flickering images raising the threat of seizure more than 3-D images."

in the Figure below, **THESE ARE**

NOT 3D SPECS !!!!!

A16 | Wednesday, November 16, 2011

THE WALL STREET JOURNAL.

ON

LETTERS TO THE EDITOR

Up the Revolution: U.S. Should Back Iran's Dissidents

Your Nov. 11 editorial "If Iran Gets the Bomb" presents thoughtful strategies to deal with Iran. However, like many who offer solutions to the problems of the Middle East, your suggestions may also be "too deep in the weeds."

Let me offer a more straightforward solution: Return Iran to being Persia. Iran's government needs to be toppled, not contained. I believe the best way to do this with minimum boots on the ground is to recognize the dissidents as the true government of the people. Then we support them in their overthrow of the theocracy, not with some covert CIA plan, but with overwhelming overt military power.

Iran has a well-educated population, with a significant

A military strike seems like the best choice for the U.S. and its allies who must halt Iran's atomic-weapon programs. But a conventional attack might not succeed and would likely provoke counterattacks. An alternative exists in a high-intensity electromagnetic pulse, created by a nuclear explosion in space

very strong policy of preventing Iran from obtaining the capability (e.g., air strikes to destroy facilities). But the term containment was originally created by State Department analyst George Kennan to describe the necessity for strong measures (including the use of military force) to prevent the spread of Soviet communism.



Machine Vision Software Drives Manufacturing

Cameras are ubiquitous on the factory floor, and for good reason: Robots, heavy machinery, raw goods, containers and finished products fly around at breakneck speed, while fewer people than ever are slowing down production by watching over them.

BY LYNN SAVAGE, FEATURES EDITOR

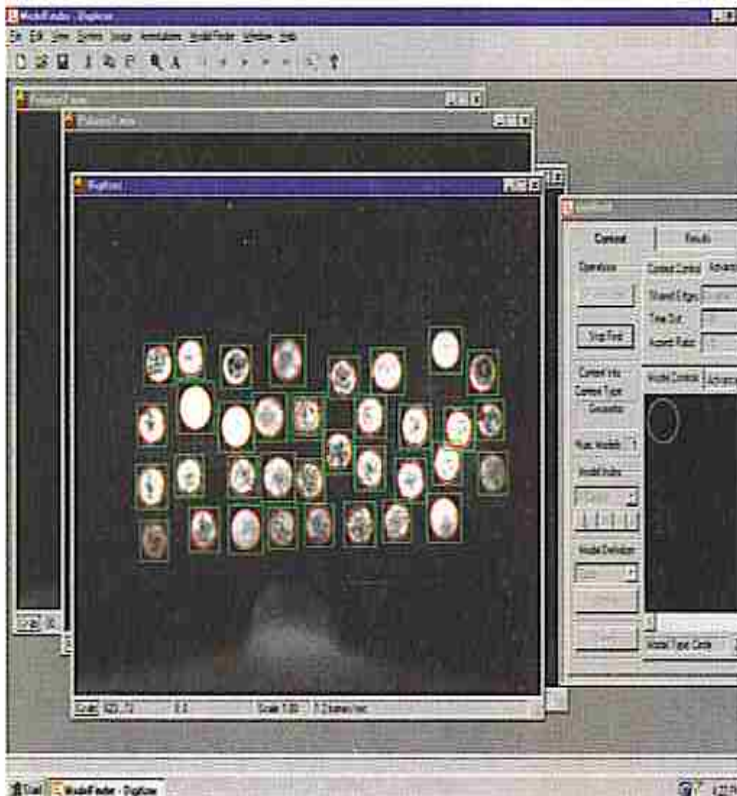
software systems featuring large suites of tools designed to make identifying and programming imaging tasks easier for the end user. Such imaging suites tend to include modules for groups of tasks that include the following:

- preprocessing images;
- matching patterns within a single image or between multiple ones;
- measuring between points on a part;
- identifying points or regions of interest;

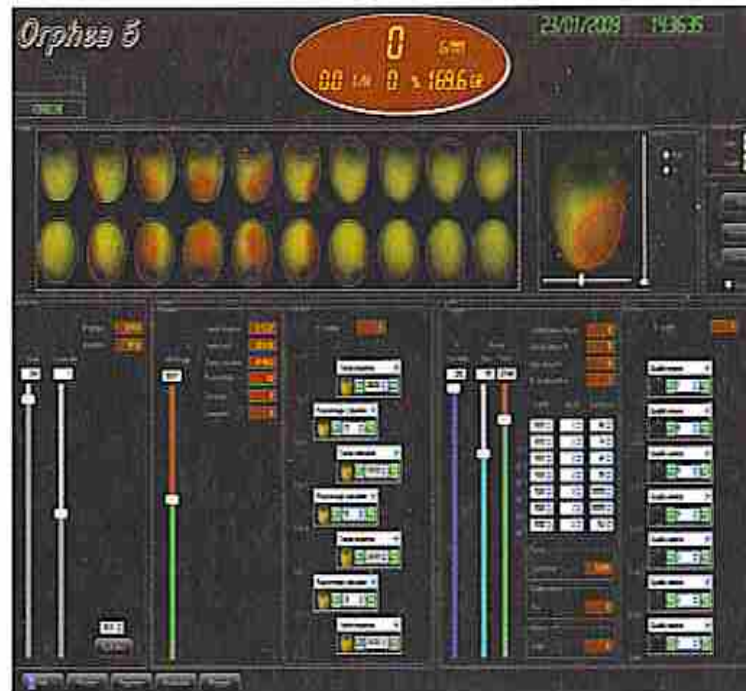44

PHOTONICS MEDIA

Photonics Spectra November 2011



Gray-scale values help determine the quality of cookies. Geometric pattern recognition locates the cookies for placement inside the trays. Courtesy of Matrox Imaging.



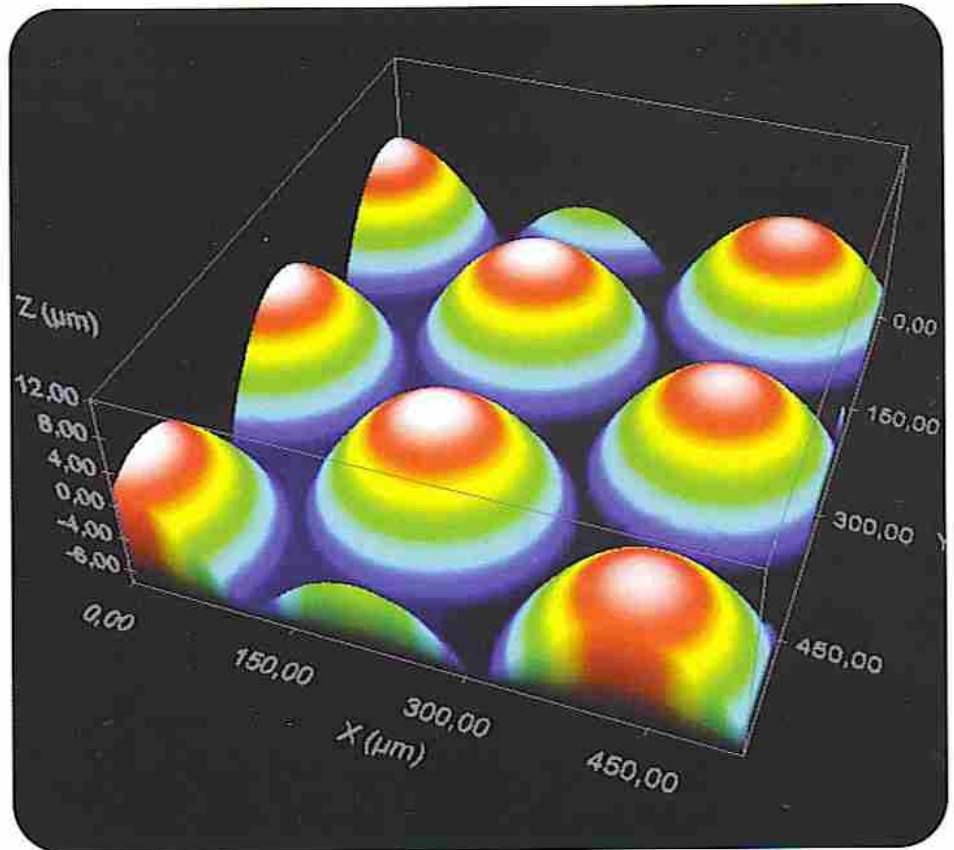
A fruit sorting and inspection system uses the Matrox Imaging Library to process images of apples. Binarization and blob analysis separate the fruit from its background and obtain dimensions like Feret diameters and elongation. Courtesy of Matrox Imaging.

Individually, micro-optics are a few millimeters in diameter at best, but together these tiny lenses comprise a powerful link to future technologies that will affect everything from advanced computers to human health.

Micro-optics permit the manipulation and management of light at a scale that allows photonic systems to more easily connect with electronics, which will help promote optoelectronic communication at faster speeds than have yet been achieved. They are an important technology for the development of improved laser beam shaping devices and optical fiber couplings, for example, and advanced micro-optics support vanishingly small endoscopy devices that help visualize diseases.

Arrays of microlenses make possible unique illumination systems as well as Shack-Hartmann wavefront sensors at the heart of optical coherence tomography systems and the adaptive optics technology that provide twinkle-free astronomy using ground-based telescopes. Micro-optics technologies also have led to the ability to manufacture tiny sensors.

6 Photonics Showcase



Microlens arrays are used for imaging, metrology and other sensor systems.
(Images: SUSS MicroOptics SA)

November 2011

November 2011


Photonics Showcase 7

machine vision for cookies and apples!...


And optics for endoscopes:
(note scale is in microns)

And a Fresnel lens for laser shaping for eye surgery

more super optics....



On wafers up to 8 in. in diameter, intricate diffractive optical elements are possible, including this Fresnel design for shaping the beam of an excimer laser.



How to Make a Spectacle of Yourself In Frames With No Glass in Them

WST

* * * 18 Nov 11

Hong Kong Eyewear Fad Is Clearly
Crazy for Some; 'I'm Deeply Confused'

By ALEX FRANGOS

HONG KONG—Most people wear glasses to see. This city's hip young crowd wears them to be seen.

That's clear when you look closely at the people crowding Hong Kong's busy shopping streets. In many cases the glasses have no glass. The plastic frames, usually in black, tortoiseshell or bright colors, are empty.

Chu Fun, a popular 32-year-old morning-radio host, wears contact lenses for nearsightedness, but she wears glasses, too, choosing from among four pairs of lensless spectacles. She bought her favorite ones, black

with purple stems, in Japan a couple of years ago for about \$13. She also has a pink pair, a black cartoonish pair and a bright red pair she picked up just the other day. Her husband has three pairs, all black but in different shapes.


Besides matching her outfits, or her hair, which until recently also was purple, the glasses are practical. She doesn't have time to put on makeup early in the morning before facing her colleagues. "Those black circles are so seriously bad, I try to find some way to cover it," she says.

The no-glass frames also don't blind the wearer when walking out of the arctic air conditioning that blasts through most buildings into the tropical heat. "If you wear this, no fog," she says.

And one more practicality: fake eyelashes. "If I have lenses here," she says, sticking her finger through the frames, lashes

Please turn to page A12

Needless Glasses Put These People in Right Frame of Mind



Raymond Chan, a nurse who has perfect vision, plays up the 'nerdy' look with his empty black frames.

The human animal is remarkable indeed, is it not? **Rimless glasses were *ne plus ultra*. Now GLASSLESS Rims are!** Rims say "I know books, I am serious, a bit smart at least, and how I look is not the very most important thing in my life... Not too long ago, the gentler sex hid its sexiness, so spectacles really took away from their main visual asset, a pretty smiling face, but not so any more. There is too much else to look at and see now, and enjoy, and be attracted to. (Job #1).



REAL MEDICAL HORROR STORIES THAT ARE TRUE

#1 See Vickie Poirer's report on strabismus surgery page 202. #2 READ THIS:

AMA Morning Rounds

Today's Medical News Prepared Exclusively for AMA Members

in affiliation with
BulletinHEALTHCARE

Dr. Paul Romano, AMA Member

Thursday, November 10, 2011

Leading the News

OMG ↓ hell on earth!

EEG may detect awareness in some patients in vegetative state.

The [New York Times](#) (11/10, A15, Carey, Subscription Publication) reports, "Three severely brain-injured people thought to be in an irreversible 'vegetative' state showed signs of full consciousness when tested with a relatively inexpensive and commonly used method of measuring brain waves," according to a [study](#) published online Nov. 10 in [The Lancet](#).

In addition, the study's findings "provide startling – and in some ways disturbing – new evidence confirming previous indications that a significant proportion of patients diagnosed as being vegetative may in fact be aware," the [Washington Post](#) (11/10, Stein) points out. Just as important, "the widely available, portable technology used in the research offers what could be the first practical way for doctors to identify and finally communicate with perhaps thousands of patients who may be languishing unnecessarily in isolation. Doctors could, for example, find out whether patients are in pain."

Followups: on ethanol insanity - the end, below! Happy holidays anyway -per

